



## C a r d i o l o g y

Feline cardiomyopathy –  
ACVIM 2020 guidelines

Cardio-oncology

Cardiohepatic syndrome  
in a chronic heart failure  
of dogs

# THE BEST CHOOSE BEST

SPECIALISED  
SUPPLEMENTS FOR  
DOGS AND CATS

- comprehensive support
- ingredients with scientifically proven effect
- convenient application (Twist off capsule)



**Dear Readers,**

The current Vet Life issue features topics related to heart diseases, i.e., a new method of classification and treatment of feline cardiomyopathy based on the American College of Veterinary Medicine (ACVIM) recommendations.

Heartworm disease in dogs and cats is another exciting matter. The impact of heart diseases on the other organs, such as the liver, is discussed in the paper "Cardiohepatic Syndrome in chronic heart insufficiency". We also recommend the paper on cardio-oncology issues entitled "Hypertension and proteinuria induced by tyrosine kinase inhibitors".

The other topics include nutritional cardiomyopathy, cough differential diagnosis or rarely reported feline polycythaemia.

We hope that diagnostic tests, supplements, and veterinary diets discussed in the Vet Pharmacy section will make the diagnostic process of your patients easier.



**Anna Rutkowska**  
Editor-in-chief

Enjoy Your reading!

**ISSUE 3/2024**

**IN EXPERT'S OPINION**

- 4 **The most important ACVIM 2020 guidelines on feline cardiomyopathy.**  
Parzeniecka-Jaworska Marta, Bindas Paulina, Pierzecka Ewelina, Dadun Marta
- 8 **Arterial hypertension and proteinuria induced by tyrosine kinase inhibitors.**  
Kapturska Karolina
- 11 **Heartworm disease: a severe disease of dogs and cats.**  
Adaszek Łukasz, Mazurek Łukasz
- 15 **Diet-associated dilated cardiomyopathy.**  
Gach Justyn, Michałek Marcin, Frydrychowski Piotr, Noszczyk-Nowak Agnieszka
- 17 **Polycythaemia Vera in the Cat: a case study and literature review.**  
Kapturska Karolina.
- 22 **The coughing dog: differentiating respiratory cough from cardiac cough.**  
Sinanis Theodoros
- 25 **Cardiohepatic syndrome in a chronic heart failure of dogs.**  
Paślowska Urszula, Paślowski Robert, Kochman Agata.

**STRAIGHT OFF THE SHELF EXPERIENCE**

- 31 **To Support or Not To Support – supplements in dogs with advanced heart failure**  
Garncarz Magdalena, Parzeniecka-Jaworska Marta

**Vet Pharmacy**

**Diagnostics**

- 32 **Test: Diagnosis of vector-born disease**
- 32 **Test: Diagnosis of diarrhea**
- 33 **Cardiac markers: Canine and Feline NT-proBNP**
- 33 **D-dimers**

**Supplements**

- 34 **CardioVet**
- 34 **HemoVet**
- 34 **RenalVet**
- 35 **Hepatiale**

**Vet Expert – new:**

- 36 **Stimuderm shampoo and serum**

**Editor address:** ul. Brukowa 36/2, 05-092 Łomianki, Poland  
**Editor-in-chief:** Anna Rutkowska, a.rutkowska@vetexpert.pl  
**Content editor:** Agnieszka Kurosad  
**Proofreading:** Dagmara Ewa Chełstowska  
**Graphic designer:** Michał Kaczor  
**Print:** KRM DRUK  
**Publisher:** Vet Planet Sp. z o.o. ul. Brukowa 36/2, 05-092 Łomianki, Poland  
**Circulation:** 2000 exemplars  
 All rights reserved. Without written permission of the publisher, no part of this publication can be reproduced. Editors reserve the right to edit submitted texts.  
 PN19893



# The most important ACVIM 2020 guidelines on feline cardiomyopathy



Marta Parzeniecka-Jaworska<sup>1</sup> DVM, PhD Paulina Bindas<sup>2</sup>, Ewelina Pierzecka<sup>2</sup>, Marta Dadun<sup>2</sup>

<sup>1</sup> Chair of Pathology and Veterinary Diagnostics, Institute of Veterinary Medicine, Warsaw University of Life Sciences  
<sup>2</sup> Scientific Association of Veterinarians, Institute of Veterinary Medicine, Warsaw University of Life Sciences

## Introduction

In 2020, the American College of Veterinary Medicine (ACVIM) published new guidelines for the classification, diagnostics, and treatment of feline cardiomyopathy. The authors discuss and summarise the most important issues contained in the above-mentioned consensus.

Cardiomyopathy is defined as a heterogeneous group of diseases characterized by changes in the structure and function of the myocardium, and their development is not affected by cardiovascular comorbidities (1).

## The classification of cardiomyopathies

The most common feline cardiomyopathy is hypertrophic cardiomyopathy (HCM), which is estimated to affect about 15% of the general feline population. It is diagnosed in up to 29% of older cats, excluding cats with arterial hypertension or hyperthyroidism (2). Feline cardiomyopathies were categorized based on the classifications applied in human medicine. However, the authors of the recommendations featured in the AVIM consensus suggested classifying feline cardiomyopathies according to the European Society of Cardiology specifications. The latter are based on a phenotype of the feline heart and are more focused on the clinical than genetic aspects (1). The classification of cardiomyopathies proposed by ESC is presented in Table 1.

Cardiomyopathies of known aetiology are categorized according to the phenotype. The aetiologies include hyperthyroidism, arterial hypertension, and genetic mutations in the MyBPC3 protein gene in Maine Coon or Ragdoll cats. On the other hand, there are also cardiomyopathies of unknown aetiology (which are reported in most cats).

If the cause of myocardial abnormalities is not known, the authors recommend describing it as 'phenotypic hypertrophic cardiomyopathy' or 'phenotypic dilated cardiomyopathy' (depending on the morphology and function of the myocardium).

If the cause of the disease is known, then the cardiac lesions are described as hypertrophic (HCM) or dilated cardiomyopathy (DCM) (depending on the morphology and function of the heart). Some cardiological patients do not fall into any

of these categories. In such a scenario, instead of defining the case as „unclassified cardiomyopathy”, the authors suggest describing it as cardiomyopathy of “unknown phenotype”, with a prior and precise description of the morphological or functional characteristics which suggest the latter phenotype (1).

Disease staging is another aspect which was specified in the 2020 ACVIM consensus. It was suggested to divide cats into groups depending on the severity of clinical symptoms. The algorithm is similar to the algorithm used to classify degenerative mitral valve disease (MVD) (2). The goal is to provide veterinarians with a protocol which enables the treatment and helps with a prognosis.

The A stage includes cats which are predisposed to cardiomyopathy (Maine Coon, Ragdoll, and British short-haired cats) but do not have any symptoms of cardiovascular diseases. The B stage refers to cats with asymptomatic cardiomyopathy. The stage is further divided into the B1 stage, i.e., cats with a low risk of congestive heart failure (CHF) or arterial thromboembolism (ATE), and the B2 stage referring to cats with a high CHF and ATE risk. The bigger the left atrium, the higher the risk is. The factors which increase the risk of CHF or ATE development are gallop rhythm, arrhythmia, deterioration of left atrium systolic function, significant hypertrophy of the left ventricle, reduction of left ventricular systolic function, spontaneous echo contrast or thrombus inside the heart chambers, regional wall

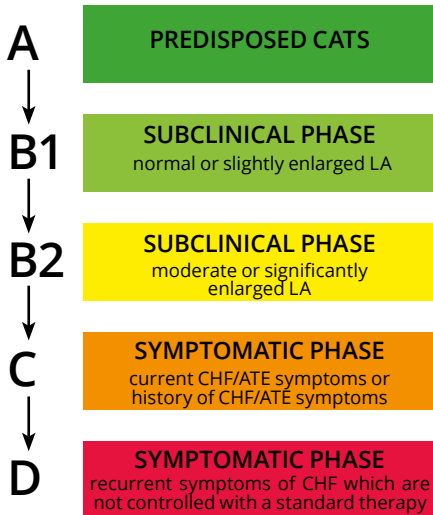
Table 1. Definitions of cardiomyopathies according to the European Society of Cardiology (ESC) (1).

Phenotype	Definition
<b>Hypertrophic cardiomyopathy, HCM</b>	General or segmental thickening of the left ventricular wall without its dilation.
<b>Restrictive cardiomyopathy, RCM</b>	
Endomyocardial form	Microscopically evident fibrosis of the endocardium which usually connects the interventricular septum with the free wall of the left ventricle; may lead to a significant reduction of the left ventricle lumen or development of aneurysm, enlargement of the left atrium or more often of the left or right atrium.
Myocardial form	Regular size of the left ventricle (including wall thickness), together with enlargement of the left atrium or both atria.
<b>Dilated cardiomyopathy, DCM</b>	Systolic dysfunction of the left ventricle is characterized by a progressive enlargement of the ventricle, a normal or thinned wall of the left ventricle, and atrial enlargement.
<b>Arrhythmogenic cardiomyopathy, AC</b> (also referred to as <i>arrhythmogenic right ventricular cardiomyopathy, ARVC</i> )	Significant dilation of the atrium and right ventricle with systolic dysfunction and thinning of the right ventricle. The lesions may also affect the left side of the heart. Arrhythmias and right-sided congestive heart failure are often reported.
<b>Nonspecific phenotype of cardiomyopathy</b>	The phenotype is not included in any phenotype class. The morphology and structural lesions of the myocardium should be precisely described.



thinning with hypokinesis of this area, and systolic function disorder. The C stage includes cats with CHF and ATE symptoms. Patients with recurrent symptoms of CHF despite the treatment are classified as the D stage (1).

Diagram 2. Stages of feline cardiomyopathies (1)  
 LA – left atrium  
 CHF – congestive heart failure  
 ATE – arterial thromboembolism



A cat with HCM may suffer from sudden cardiac death (SCD), and the risk factors are syncope, ventricular rhythm disturbances, widening of the left atrium, and regional hypokinesis of the left ventricle (2, 3).

Cats with symptomatic congestive heart failure associated with stress, intravenous fluid therapy, general anaesthesia or glucocorticoid therapy usually have a longer life span than cats in which the development of symptomatic CHF has not been impacted by these factors (1).

The examination of choice for diagnosing cardiomyopathy is echocardiography; however, making the diagnosis of various phenotypes may be a challenge (1, 4).

The treatment of arterial thrombosis and congestive heart failure does not differ significantly in various types of cardiomyopathies. Establishing a diagnosis of the specific phenotype of cardiomyopathy helps determine how the disease will further develop, give the prognosis, and create a diagnostic plan with additional tests such as blood pressure measurements or serum thyroxin level (1).

Cats of predisposed breeds (i.e., Ragdoll and Maine Coon) kept for breeding (high level of evidence, LOE) should be tested for MyBCP3-A31P and MyBPC3 R820W mutations. The goal is to reduce the prevalence of these mutations and hypertrophic cardiomyopathy in the discussed breeds (1, 4).

The above-mentioned test is useless in the breeds other than the predisposed ones since these mutations are breed-specific (1, 4).

## Diagnostics of cardiomyopathies:

The patient's medical history may not raise any concerns, particularly in the animals with HCM. The most common symptoms include problems with respiration and unspecific symptoms such as hiding or lack of appetite. Respiratory problems usually result from congestive heart failure. Paresis or paralysis due to arterial embolism (ATE) are also commonly reported. Infrequent symptoms include syncope and sometimes sudden death. (1)

A clinical examination including auscultation is always considered the first basic screening investigation in patients with a suspected heart disease. However, it does not always allow to differentiate between healthy cats and cats with cardiomyopathy.

Systolic murmurs heard in the parasternal area are reported in 30 to 45% of healthy patients and even in 80% of patients with subclinical hypertrophic cardiomyopathy (HCM). A gallop rhythm is very rarely found in healthy cats whereas it occurs in 2.6-19% of cats with subclinical hypertrophic cardiomyopathy. Due to accelerated heart rhythm, it may be sometimes difficult to differentiate between a gallop rhythm and other arrhythmias. The arrhythmias may also be related to cardiomyopathies (1).

It should be emphasized that it is not possible to detect abnormal findings of auscultation in many cats with hypertrophic cardiomyopathy (HCM). However, if some murmurs are found in any cat (medium LOE), further diagnostic examinations should be performed. (1).

A loud systolic murmur (3-4/6 grade) is typical for cats with hypertrophic cardiomyopathy. Very loud murmurs causing the so-called 'cat's purring', i.e., palpable thorax tremor (grade 5 – 6/6 murmur), are probably related rather to the congenital heart defect than cardiomyopathy. Moreover, audible murmur may not be present in cats with more advanced disease (1).

In cats with left-sided heart disease, the typical symptoms found on clinical examination include increased respiration rate and breathing difficulties. A comparison between the patients with subclinical HCM and the ones affected with left-sided heart failure, in the latter, gallop rhythm or audible arrhythmia are more common whereas murmurs are less frequent. (1).

Lung oedema is accompanied by pulmonary crackles while normal respiratory sounds and heart sounds are suppressed when fluid accumulates in the pulmonary cavity (1)

Cardiomegaly and bulging of the left atrial auricle in the ventrodorsal and dorsoventral views on X-ray may suggest cardiomyopathy. However, the radiological examination is not the best tool to detect mild cardiomyopathy-related lesions. Left-sided heart failure can develop even with no visible lesions on X-ray. It is also impossible to define any cardiomyopathy phenotype based on the heart shape. The cur-

rent concept of a "Valentine's Day" shape of the heart in hypertrophic cardiomyopathy has turned out to be incorrect (1).

Radiographic imaging is considered a gold standard for confirming cardiogenic pulmonary oedema. If performing a radiological examination is not safe, it should be postponed (low LOE). In cats, the radiographic image will vary a lot (1).

Differential diagnostics of cardiological and non-cardiological causes of respiratory failure include quantitative measurement of feline NT-proBNP in plasma or pulmonary liquid. This examination provides fast and reasonably accurate results. However, it should be the first-choice test only when the staff is under time pressure. In subclinical hypertrophic cardiomyopathy, time is not that important, and therefore, NT-proBNP measurements will be performed unless the ultrasound examination is available. (1,5).

Measuring the concentration of cardiac troponin I (cTnI) is indicated only when the results can arrive fast. It is possible to use highly sensitive tests to measure the level of human cardiac troponin I and to differentiate between patients with subclinical hypertrophic cardiomyopathy and healthy patients. The increased level of troponin is associated with a higher risk of death caused by cardiovascular diseases (1).

Electrocardiography (ECG) demonstrates low sensitivity in detecting hypertrophy of the left ventricle or enlargement of the left atrium. Therefore, it is not recommended as a screening test for feline cardiomyopathy. ECG is important in detecting arrhythmias which may be associated with cardiomyopathies and cause weakness and syncope. The heart rhythm may be also monitored at home using the plate with electrodes, and the results of measurements can be analysed with mobile applications (1).

Systemic hypertension is reported in 85% of cases with general or segmental left ventricular hypertrophy, and it is usually mild or moderate. Blood pressure should be measured in all cats with thickened left ventricular wall.

Hyperthyroidism is very common in geriatric patients, and it is associated with abnormalities detected upon auscultation (murmurs, additional tones, arrhythmia), heart remodelling (left ventricular hypertrophy or lumen enlargement in both ventricles), and left-sided heart failure or arterial thrombosis. Severe left ventricular hypertrophy can result from the exacerbation of hypertrophic cardiomyopathy related to hyperthyroidism. A standard approach should include measuring serum thyroxin in cats over 6 years of age, with concurrent abnormal heart auscultation results or hypertrophy of the left ventricle upon echocardiography. (1)

The echocardiographic examination is the gold standard in feline cardiomyopathy diagnostics. To make it as reliable as possible,

the investigation should be performed by competent specialists without sedation and undue restraint and in a peaceful manner. Positioning the patient in lateral recumbency or standing position does not affect the examination result (1, 4).

Measurements of the left ventricular wall thickness are taken with 2D echocardiographic images in M-mode. Due to the regional heterogeneity of left ventricle hypertrophy in many cats with hypertrophic cardiomyopathy, M-mode measurements may overlook segmental wall thickness. Therefore, the 2D technique should be used to measure the left ventricular wall thickness (1, 4).

In pedigree cats, basic echocardiography should be performed as a screening tool, including:

- the size of the left atrium,
- thickness of the left ventricle wall,
- diameter of the left ventricle lumen,
- left atrial fractional shortening,
- left ventricular fractional shortening.

Additionally, a qualitative evaluation of the cardiac geometry and potentially of SAM (systolic anterior motion of the mitral valve towards the septum) can be performed. It should be kept in mind that any common threshold value for the normal thickness and hypertrophic thickness of the left ventricle wall has not been determined. In most cats, the normal values of end-systolic thickness of the left ventricle wall are below 5 mm, and the values above 6 mm suggest hypertrophy. However, it is recommended to relate the above-mentioned values and the results between 5 and 6 mm to the cat's body weight, medical history, qualitative evaluation of LA and LV morphology and function, presence of DLVOTO, and velocity measurements with Doppler imaging.

A more detailed echocardiography examination should be performed in cats when the clinician suspects cardiomyopathy based on the history and clinical examination. The examination can be also performed in older patients before the procedures under general anaesthesia, fluid therapy, and treatment with sustained-release corticosteroids. The measurements which should be taken during the examination are provided in Table 1. A shortened version is reserved for patients in a bad medical state and with a suspicion of heart failure. The following parameters are then determined: size of the left atrium, systolic function of the left ventricle, presence of pleural and/or pericardial effusion, and B-line artefacts. Once the patient is stabilized, a complete echocardiographic examination should be performed following the protocol recommended for cats with suspected cardiomyopathy (Diagram 3).

### Diagnosics of subclinical cardiomyopathy

A diagnosis of subclinical cardiomyopathy in cats may be a challenge for veterinarians. Diagnosics of heart diseases should be prompted by the history and clinical symp-

Table 3. Indications for echocardiologic examination (1)

<b>History</b>	<ul style="list-style-type: none"> <li>• Syncope</li> <li>• Seizures (without any other neurological abnormalities)</li> <li>• Diagnosis of cardiomyopathy in close relatives</li> <li>• Weakness</li> <li>• Intolerance of physical exercise / open-mouth breathing</li> <li>• Intolerance of parenteral fluid therapy</li> <li>• A pedigree cat for breeding</li> <li>• Maine coon or Ragdoll with MyBPC3 mutation</li> <li>• Endocrinopathies</li> <li>• Testing positive for heartworms</li> <li>• Fever of unknown origin</li> </ul>
<b>Clinical examination</b>	<ul style="list-style-type: none"> <li>• Murmurs</li> <li>• Gallop sound or systolic click</li> <li>• Muffled heart murmurs or respiratory sounds</li> <li>• Arrhythmia</li> <li>• Tachypnoea</li> <li>• Crackles over lungs</li> <li>• Distention of jugular veins or pulsation</li> <li>• Ascites</li> <li>• Hypo- or hyperkinetic arterial pressure on the femoral artery</li> <li>• Acute paresis/paralysis</li> <li>• No pulse in the femoral artery</li> </ul>
<b>Cats over 9 of age undergoing procedures which might cause CHF</b>	<ul style="list-style-type: none"> <li>• General anaesthesia</li> <li>• Fluid therapy</li> <li>• Sustained-release glucocorticoids</li> </ul>

Table 4. Indications for echocardiologic examination (1)

<b>Echocardiographic examination performed in cats with suspected cardiomyopathy:</b>		
<b>Standard measurements</b>	<b>Quantitative measurements</b>	<b>Qualitative evaluation</b>
	<b>M-mode:</b> <ul style="list-style-type: none"> <li>• IVSd</li> <li>• LVFWd</li> <li>• LVIDd</li> <li>• LVIDs</li> <li>• LV FS%</li> <li>• LA FS%</li> </ul> <b>2D:</b> <ul style="list-style-type: none"> <li>• IVSd</li> <li>• LVFWd</li> <li>• LVIDd</li> <li>• LVIDs</li> <li>• LA/Ao</li> <li>• LA diameter in parasternal projection in a long axis</li> </ul>	<b>Findings including:</b> <ul style="list-style-type: none"> <li>• hypertrophy of papillary muscles</li> <li>• systolic loss of the left ventricle lumen</li> <li>• SAM</li> <li>• dynamic RVOTO</li> <li>• abnormal cardiac ventricular geometry</li> <li>• spontaneous echo contrast or thrombus</li> <li>• segmental abnormalities in wall mobility</li> </ul>
<b>Additional (performed by a specialist in cardiology)</b>	<b>Additionally: Spectral doppler:</b> <ul style="list-style-type: none"> <li>• mitral valve inflow speed</li> <li>• isovolumetric diastolic time</li> <li>• LVOT flow speed</li> <li>• RVOT flow speed</li> <li>• PVF flow speed</li> <li>• LAA flow speed</li> </ul> tissue Doppler imaging	

toms suggesting cardiomyopathy (galloping heart rhythm, heart murmurs, and arrhythmia). The examination can be performed before anaesthesia or intravenous fluid therapy in patients with suspected congestive heart failure. In cats, the most precise examination allowing for a diagnosis of cardiomyopathy is echocardiography. The operator's skills are a

key factor which determines the detectability of the disease. After proper training, even a basic examination performed by the veterinarian can play an important role in improving the accuracy of cardiomyopathy diagnostics. The preliminary diagnosis should be then confirmed by a complete echocardiographic examination performed by the specialist.





If echocardiography cannot be performed, measuring blood NT-proBNP concentration should be considered. The test can be used as the initial screening tool in cats with suspected cardiomyopathy, but it cannot serve to differentiate the degree of disease severity. It should be remembered that in cats, normal values do not rule out cardiomyopathy, in particular a mild form of the disease. It is always recommended to perform echocardiography when the test for NT-proBNP yields a positive result.

In older cats with heart murmurs, galloping heart rhythm or arrhythmia, it is additionally recommended to check serum T4 concentration and measure blood pressure.

## Diagnosics of suspected congestive heart failure

The symptoms of congestive heart failure include accelerated and heavy breathing, hypothermia, galloping heart rhythm, and crackles over the lungs upon auscultation. Radiological examination of the thorax is the gold standard in diagnostics of cardiogenic pulmonary oedema. Pulmonary infiltrations and cardiomegaly are seen in the radiological examination of patients with oedema. If the examination is too risky for the patient due to dyspnoea, an ultrasound examination of the thorax should be considered or NT-proBNP concentration can be determined. The following findings on the ultrasound examination may suggest pulmonary oedema: effusion and B-line artefacts in combination with left atrium enlargement. Determination of NT-proBNP allows for defining the cause of respiratory failure; with a negative result, a disease of the respiratory tract is more probable than a cardiac condition. Ultrasound examination should follow the above-discussed guidelines, once the cat with suspected congestive heart failure is stabilized (Table 1).

## Therapy

According to the latest recommendations of ACVIM, medical treatment should not be implemented for B1-stage cardiomyopathy. However, it is important to monitor the patient for left atrial enlargement in particular by performing the annual echocardiographic follow-up.

At the B2 stage, LA becomes moderately or markedly enlarged, so the risk of arterial thromboembolism (ATE) increases. The risk is greater if echocardiography additionally shows a reduction of LA systolic fraction and spontaneous echo contrast (SEC). Having that in mind, it is recommended to start anticoagulation therapy, e.g., clopidogrel at a dose of 18.75 mg/kg every 24 hours. For patients with a very high risk of ATE, two anticoagulation drugs (e.g., clopidogrel and aspirin or clopidogrel and factor Xa inhibitor) are additionally suggested. Apart from the anticoagulation therapy, no other medications are recommended at stage 2. According to the available studies, the ad-

ministration of ACE or spironolactone in cats with subclinical heart disease does not affect the systolic function of the left atrium or the time of the effective treatment. It is important to monitor the patient by performing follow-up echocardiography examinations. Stress related to the examination and the ways to minimize it (e.g., with gabapentin) should be addressed when the follow-up visits are scheduled.

Treatment against pulmonary oedema should be instituted as soon as possible in a patient presenting the symptoms of acute heart failure (accelerated respiration dyspnoea, hypothermia, galloping heart rhythm). According to the ACVIM recommendations, if CHF is suspected, the treatment can be implemented based on the clinical symptoms even when the veterinarian cannot perform additional examinations (chest X-ray, heart echocardiography). Ideally, blood is collected in advance and kidney function is assessed unless it poses a risk for the patient; however, in acute heart failure, it is recommended to administer diuretics even with concurrent azotaemia. Furosemide is the medication of choice, and it is given intravenously at a dose of 1-2 mg/kg. If dyspnoea results from hydrothorax, thoracocentesis should be performed. Additionally, in all cats with dyspnoea, oxygen therapy is started, and pharmacological sedation can be considered (e.g., administration of butorphanol). During the treatment, it is also important to minimize stress related to hospitalization (delicate handling, quiet facilities, providing shelter in a cage). In the case of pulmonary oedema or hydrothorax secondary to heart failure, fluid therapy is contraindicated. During hospitalization, the patient's medical status, including body temperature, heart rate, respiration rate, blood pressure, body weight and urine volume, should be continuously monitored.

If heart failure with low cardiac output is suspected (hypotension, hypothermia, bradycardia), administration of pimobendane can be considered unless there is a dynamic left ventricular outflow tract obstruction (DLVOTO). If the patient does not improve clinically after starting pimobendane therapy, continuous intravenous infusion of dobutamine can help. Transdermal application of nitroglycerine is not recommended due to the lack of clear evidence for its efficacy.

Due to hospitalization-related stress in cats, the patient should be sent home once they are stabilized. The recommendations for owners should emphasize the need to monitor the cat's respiration rate upon rest and during sleeping (it should not exceed 30/min). A follow-up visit should take place within 3-7 days after hospitalization and include an evaluation of the cardiac and kidney function (urine, creatinine, and electrolyte concentrations in the blood). In patients without significant clinical obstruction of the left ventricular outflow tract, pimobendane at a dose of 0.625-1.25 mg PO can be administered every 12 hours. The efficacy of ACE medications in case of chronic heart failure has not been demonstrated, al-

though some veterinarians use them. It should be noted that in every cat with CHF and moderate or significant left atrial enlargement, the above-mentioned anticoagulation therapy should be introduced. Besides, in cats with the DCM phenotype, history includes questions about the diet, and if necessary, taurine can be supplemented. A follow-up examination in patients with chronic heart failure should be performed every 2 to 4 months.

At the last stage of therapy-resistant cardiomyopathy, instead of high doses of furosemide (>6 mg/kg), torsemide can be administered orally at a dose of 0.1-0.2 mg/kg every 24 hours, and the target doses can be determined based on the clinical symptoms. Additionally, spironolactone (1-2 mg/kg PO every 24 h) may be given. In cats with diastolic dysfunction of the left atrium, it is recommended to use pimobendane. It is worth starting taurine supplementation at a dose of 250 mg every 12 hours and avoiding a high amount of salt in the diet. It is important to control body weight and assess the cat's condition on the BCS scale upon subsequent visits, since due to the cardiac disease, cachexia may develop. Therefore, it is also important to provide a sufficient number of calories (it should even be more important than avoidance of excessive amounts of sodium). During the follow-up visits, it is recommended to control serum potassium concentration and start its supplementation in case of hypokalaemia.

## Summary:

The diagnosis and treatment of heart diseases in cats is a great challenge for veterinarians. The clinical symptoms in this species are often poorly visible, and preventive examinations are mainly performed by the owners of pedigree cats. Therefore, it is important to know the guidelines for the diagnostics and monitoring of feline cardiomyopathies.

### References:

1. V. L., J., Chetboul V., Côté E., Fox P.R., Häggström J., Kittleson M.D., Schober K., Stern J.A.- ACVIM consensus statement guidelines for classification, diagnosis and management of cardiomyopathies in cats,
2. Noszczyk-Nowak A., Bubak J., Michatek M., Frydrychowski P., Ciepil-Kośmiejka A., Janus I., "Podsumowanie nowych wytycznych ACVIM"
3. Payne J. R., Borgeat K., Connolly D.J. et al.: Prognosis indications in cats with hypertrophic cardiomyopathy. "J Vet Intern Med", 2013, 27, 1427-1436.
4. Jens Häggström, Virginia Luis Fuentes, Gerhard Wess, Screening for hypertrophic cardiomyopathy in cats, Journal of Veterinary Cardiology Volume 17, Supplement 1, December 2015, Pages S134-S149
5. G.E. Singletary, J.E. Rush, P.R. Fox, R.L. Stepien, Effect of NT-pro-BNP Assay on Accuracy and Confidence of General Practitioners in Diagnosing Heart Failure or Respiratory Disease in Cats with Respiratory Signs, Journal of the Veterinary Internal Medicine Volume 26, Issue 3, May-June 2012, Pages 542-546

# Arterial hypertension and proteinuria induced by tyrosine kinase inhibitors

Karolina Kapturska DVM

Veterinary Clinic „NEOVET” s.c. Hildebrand, Jelonek, Michalek-Salt  
Department of Veterinary Medicine, University of Life Sciences in Wrocław



## Introduction

Cardio-oncology is a new field of clinical sciences dedicated to monitoring, diagnostics and treatment of cardiovascular diseases resulting from the adverse effects of cytostatic medications or radiotherapy in oncological patients. Many anticancer drugs e.g., anthracyclines, alkylating agents, or tyrosine kinase inhibitors (TKI) are cardiotoxic. Tyrosine kinase inhibitors (TKI) are used in human oncology for the treatment of kidney cancer, breast cancer, and gastrointestinal stromal tumours (GIST) and in the management of some leukaemia types (1-4). In veterinary medicine, toceranib and masitinib approved for inoperable or recurrent Patnaik grade 2 or 3 mast cell tumours (mastocytoma, MCT) are commonly used (5). In clinical practice, it has been attempted to use these substances off-label in other types of cancer (including heart base tumours or angiosarcomas) (6, 7) or even in canine atopic dermatitis (8). Toceranib (Palladia) can inhibit VEGFR-2, PDGFR- $\beta$ , and Kit receptor (9). Interestingly, it is an analogue of sunitinib which is used in human oncology and is proven to have an antihypertensive effect; however, it is associated with the development of nephrotic syndrome and glomerulosclerosis (9, 10). In dogs, there are reports of azotaemia, protein-losing nephropathy or hypertension induced by this drug (11-13). Masitinib can inhibit the CD117 (c-kit) receptor. Its mutation or overexpression is an underlying mechanism of oncogenesis in mastocytoma (14, 15). Furthermore, it is also a blocker of  $\alpha$  and  $\beta$  platelet-derived growth factor receptors (PDGFRs), a wild and mutated form of fibroblastic growth factor receptor (FGFR3), and intracellular Lyn kinase (16-18). In dogs, adverse effects of this drug include proteinuria, nephrotic syndrome, and kidney failure (5, 18, 19).

## Cardiotoxicity of TKI in people

Oncological patients managed with TKI show a 4-fold increased risk of arterial hypertension, a 2.5-fold increased risk of systolic left ventricle dysfunction (defined as a decrease of systolic fraction, EF%), and a 2-fold increased risk of ischaemic cardiac episodes compared to patients receiving standard chemotherapy (20, 21). Moreover,

the TKI treatment has been associated with a higher risk of thrombosis, arrhythmogenic activity (atrial fibrillation, prolongation of QTc) or development of precapillary pulmonary hypertension (1, 4, 22, 23). In patients affected by cardiotoxicity, risk factors such as coronary disease, hypertension, diabetes, or thrombosis of deep veins have played an important role (1, 4, 23-25).

The increase in arterial pressure is one of the most common side effects and depends on the type of active substance. It occurs in 4% (imatinib) to 68% (Lenvatinib) of patients (4, 26). In the case of anti-VEGF, a mean TKI increase of 8.5 mmHg and 6.7 mmHg has been reported for systolic and diastolic arterial pressure, respectively (27). The mortality rate of patients managed with TKI due to cardiovascular complications is low and does not exceed 0.3% (28, 29).

## Pathomechanism of the TKI side effects

The underlying mechanism of the above-mentioned abnormalities is not clear. Apart from the inhibition of the c-KIT receptor, *in vitro* studies have demonstrated an inhibitory effect of masitinib on some other target cells ( $\alpha$  and  $\beta$  PDGFR Lyn kinase, and FGFR3) (16). The renal tubule cells show expression of c-kit whereas PDGFs have been detected in the renal glomeruli of primates; the inhibition of the receptor might theoretically lead to the reduction of podocytes integrity and as a consequence to proteinuria, which corresponds to the changes seen under the electron microscope (5, 32-34). Therefore, it may result in direct inhibition of the c-KIT within the renal tubules and the PDGF receptors in the glomerulus (5, 33, 34).

Another theory explaining the above effect is based on the capability to induce arterial hypertension through an interaction with the other target particles, which also takes place in people (11, 32, 35, 36); however, in two cases of masitinib-associated proteinuria, no concurrent arterial hypertension has been found in dogs (5, 32, 33). The discussed phenomenon may be explained by a higher selectivity of masitinib and the lack of impact on VEGFR. A signalling tract of the latter has been suggested as the main mechanism of TKI-induced hypertension (16, 32).

It has been observed that in patients with hypertension induced by TKI, the concentration of plasma endothelin-1 increases, and the renin-angiotensin-aldosterone (RAA) axis becomes activated (4, 37, 26). The increased concentration of endothelin-1 leads to contraction of blood vessels, disturbance of water and electrolyte metabolism, and remodelling of the target organ vessels (TOD, target organ damage) and results in the increase of arterial blood pressure (37). The RAA system function is based on up-regulation, and it is a main regulator of vascular tension via angiotensin and water and electrolytes metabolism through the release of aldosterone (38). Angiotensin II provides a short-term, immediate regulation of pressure, and the mechanism maintaining sodium and volume homeostasis provides long-term control (39). Furthermore, with anti-VEGF TKI, there are three mechanisms leading to hypertension, and they include disturbance of the balance between vasodilators and vasoconstrictors, the increase of resistance in the peripheral vessels, and an injury of the blood vessels providing blood to the kidneys, which reduces the glomerular filtration rate (GFR) and triggers the activation of the RAA axis (27).

## TKI-dependent nephrotic syndrome

Nephrotic syndrome (NS) is extremely rarely diagnosed in dogs and is defined as a coexistence of hypoalbuminemia, proteinuria, leakage of fluid from the intravascular space (ascites in 75% of cases), and hypercholesterolaemia (40). Although few cases of masitinib-induced NS have been reported in dogs, it was not until 2021 when similar changes were described in an 8-year-old Labrador managed with toceranib for the first time (5, 9). The dogs have been presenting with apathy, lack of appetite, gastrointestinal symptoms (diarrhoea, vomiting), polyuria, polydipsia and enlarged abdominal circumference. The blood tests demonstrate a significant increase in renal parameters (urea, creatinine, phosphorus), hypercholesterolemia, and hypoproteinaemia (5). The increase of urine protein to creatinine ratio (UPC) can sometimes be substantial, reaching values higher by 180 times than the reference threshold (5). Nephrotic syndrome may subside when TKI is with-



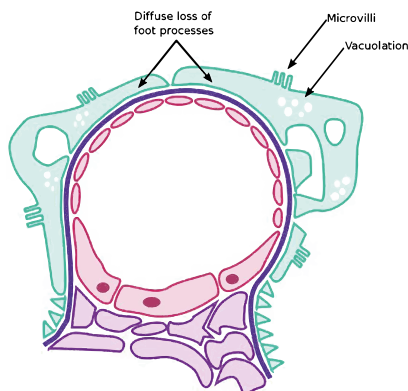
drawn and, a symptomatic treatment is implemented; however, the risk of a neoplastic disease progression is high, and it may lead to euthanasia of the animal (9).

## TKI-dependent proteinuria

TK-induced proteinuria caused by masitinib and toceranib has been reported in both dogs and cats (13, 17, 32). In a retrospective study from 2018, 24% of dogs managed with toceranib showed proteinuria in the follow-up urinalyses and UPC ratio from 0.6 to 4.9 (the mean of 0.75). Unfortunately, no changes in arterial pressure were described in the study group (13). The treatment with masitinib was related to proteinuria in a slightly lower percentage (18%) of dogs (it was also assessed based on the increase of UPC ratio above the reference value) (32). It should be emphasized that in the mentioned study, the reduction of blood albumin concentration was found only in one dog, and none of the dogs presented with oedema, ascites or azotaemia. Interestingly, in the patients with a higher UPC ratio before the treatment, exacerbation of proteinuria was not observed; however, the scenario can also happen (32).

## Histopathological lesions

There are few reports on the type of histopathological lesions in the kidneys of dogs managed with masitinib. 'Minimal change nephropathy' has been reported in a Giant Schnauzer and Labrador retriever (33, 34). A histopathological examination revealed oedema of the podocytes, thickening and separation of the basal membrane in the Bowman's capsule, and mild oedema of the epithelial cells in the proximal tubule. The examination under an electron microscope showed typical exfoliation of the podocytes, cellular oedema, and deformation of the microvilli. Furthermore, in the Labrador retriever case, typical signs of interstitial nephritis and microthrombi were observed (5, 33, 34).



## TKI in cats

Although masitinib is not approved for cats, its use is reported in the species, e.g., in lymphomas with a high percentage of large granular lymphocytes (LCL, large granular

lymphoma) (41). In addition, due to the high selectivity of masitinib for inhibition of the PDGFR signalling pathway, in the future, it may help in the treatment of post-vaccination sarcomas thanks to dysregulation of the pathway in tumour cells. The results of in vitro studies have confirmed the efficacy of masitinib in inhibiting the growth and phosphorylation of PGDFR in the post-vaccination sarcoma cell lines (42).

Apart from the mild gastrointestinal symptoms and neutropenia, clinically significant proteinuria within 4 weeks from starting the therapy has been reported in 10% of the study group (2/10 cats) in the studies on the safety of masitinib in cats. A significant increase in creatinine correlated with a reduction of serum albumin concentration has also been demonstrated with the results still in the reference range (17).

Toceranib shows a therapeutical potential in cats suffering from oral squamous cell carcinoma, mastocytoma, pancreas adenocarcinoma, and post-injection sarcomas like masitinib (43-46).

Studies investigating the efficacy and safety of toceranib in feline patients have shown side effects, such as gastrointestinal disorders, hepatotoxicity, and myelosuppression (47). Holterman et al. (2016) reported proteinuria (stages 1 and 2 on the four-point scale) in 67% of the cats managed with toceranib. Furthermore, 17% of the cats showed an increase in serum urea concentration (17%), and in the isolated cases, an increase in creatinine, hypoalbuminemia and UPC ratio was observed (46). None of the authors evaluated the impact of the drug on arterial pressure, so further studies are warranted to evaluate a potential hypertensive effect in this species.

## Summary and clinical treatment recommendations

Cardio-oncology is a new and emerging field of clinical sciences, and until now, there are no guidelines on monitoring the veterinary patients managed with TKI; the first publications discussing the topic have emerged in human medicine. Before starting the treatment, it is recommended to perform comprehensive laboratory and imaging diagnostics (echocardiography, electrocardiography, chest X-ray), since it is essential to exclude patients with NYHA class III and IV heart failure (28, 48). The administration of TKI is not recommended for patients with significantly reduced exercise capacity who suffer from weakness, palpitation, or dyspnoea at rest or with minimum physical exertion (49). In 50% of the patients presenting with the symptoms of cardiovascular failure during the treatment with TKI, the therapy was continued along with an appropriate cardiological treatment (28, 48). Calcium channel blockers and potassium-sparing diuretics have demonstrated

the highest efficacy in reducing hypertension induced by the anti-VEGF TKI (27). Left ventricle dysfunction usually develops within the first weeks of therapy, and therefore, close cardiological monitoring of the patients is recommended at the initial phase of treatment (4).

Despite the lack of clear and consistent guidelines for monitoring the veterinary patients managed with TKI, it is recommended to perform urinalysis together with the UPC ratio measurement in the first month of treatment, basic blood work (the measurements of urine and creatinine concentration in the blood serum), measurement of arterial blood pressure and control of the animal body weight (5, 9, 17, 18). The detection of changes in the UPC ratio in regular analyses can be an early marker of dysfunction of the urinary system in dogs managed with masitinib (50). It should be remembered that animals suffering from an early stage of renal failure due to TKI do not necessarily demonstrate an increase of urine or creatinine concentration above the reference values; however, a significant increase compared to the previous analysis in a given patient should be alarming for a veterinarian (5, 17, 19, 34).

If the UPC ratio is above 0.5, it is recommended to perform the analysis again after one week, and with persisting proteinuria, it is advocated to start the treatment with the reduction of TKI doses or withdrawal of the medication (9). Kuijlaars et al. (2021) reported a significant improvement in the urinalysis results in dogs with UPC > 2.0 after withdrawal of the medications. Enalapril, an inhibitor of angiotensin-converting enzyme (ACEI), is used at a dose of 0.5 mg/kg of body weight in patients with isolated proteinuria, and with concurrent arterial hypertension, amlodipine is also included in the management (51).

## References:

- Zamorano, J.L.; Lancellotti, P.; Muñoz, D.R.; Aboyans, V.; Asteggiano, R.; Galderisi, M.; Habib, G.; Lenihan, D.J.; Lip, G.Y.H.; Lyon, A.R.; et al. 2016 ESC Position Paper on cancer treatments and cardiovascular toxicity developed under the auspices of the ESC Committee for Practice Guidelines. *Eur. Heart J.* 2016, 37, 2768–2801.
- Curigliano, G.; Cardinale, D.; Dent, S.; Criscitello, C.; Aseyev, O.; Lenihan, D.; Cipolla, C.M. Cardiotoxicity of anticancer treatments: Epidemiology, detection, and management. *CA Cancer J. Clin.* 2016, 66, 309–325.
- Chaar, M.; Kamta, J.; Ait-Oudhia, S. Mechanisms, monitoring, and management of tyrosine kinase inhibitors-associated cardiovascular toxicities. *Oncotargets Ther.* 2018, 11, 6227–6237.
- Bohdan, M.; Kowalczyk, A.; Mickiewicz, A.; Gruchala, M.; Lewicka, E. Cancer Therapy-Related Cardiovascular Complications in Clinical Practice: Current Perspectives. *J Clin Med.* 2021;10(8):1647. Published 2021 Apr 13. doi:10.3390/jcm10081647
- Devine, L. & Polzin, D. J. (2016) Presumed masitinib-induced nephrotic syndrome and azotemia in a dog. *Canadian Veterinary Journal* 57, 752-756

6. Lew FH, McQuown B, Borrego J, Cunningham S, Burgess KE. Retrospective evaluation of canine heart base tumours treated with toceranib phosphate (Palladia): 2011-2018. *Vet Comp Oncol*. 2019 Dec;17(4):465-471. doi: 10.1111/vco.12491. Epub 2019 Jun 18. PMID: 31069932.
7. Gardner HL, London CA, Portela RA, Nguyen S, Rosenberg MP, Klein MK, Clifford C, Thamm DH, Vail DM, Bergman P, Crawford-Jakubiak M, Henry C, Locke J, Garrett LD. Maintenance therapy with toceranib following doxorubicin-based chemotherapy for canine splenic hemangiosarcoma. *BMC Vet Res*. 2015 Jun 11;11:131. doi: 10.1186/s12917-015-0446-1. PMID: 26062540; PMCID: PMC4464614.
8. Daigle J, Moussy A, Mansfield CD, Hermine O. Masitinib for the treatment of canine atopic dermatitis: A pilot study. *Vet Res Commun* 2010;34:51-63
9. Remerowski SM, Herrera CL, Donnelly LL. Toceranib phosphate-associated nephrotic syndrome in a dog: a case report. *BMC Vet Res*. 2021 Apr 7;17(1):146. doi: 10.1186/s12917-021-02850-9. PMID: 33827545; PMCID: PMC8208059.
10. Estrada CC, Maldonado A, Mallipattu SK. Therapeutic inhibition of VEGF signaling and associated Nephrotoxicities. *J Am Soc Nephrol*. 2019;30(2):187-200. doi: 10.1681/ASN.2018080853.
11. Tjostheim, S. S., Stepien, R. L., Markovic, L. E., et al. (2016) Effects of Toceranib phosphate on systolic blood pressure and proteinuria in dogs. *Journal of Veterinary Internal Medicine* 30, 951-957
12. London CA, Malpas PB, Wood-Follis SL, Boucher JF, Rusk AW, Rosenberg MP, Henry CJ, Mitchener KL, Klein MK, Hintermeister JG, Bergman PJ, Couto GC, Mauldin GN, Michels GM. Multi-center, placebo-controlled, double-blind, randomized study of oral toceranib phosphate (SU11654), a receptor tyrosine kinase inhibitor, for the treatment of dogs with recurrent (either local or distant) mast cell tumor following surgical excision. *Clin Cancer Res*. 2009;15(11):3856-3865. doi: 10.1158/1078-0432.CCR-08-1860.
13. Piscocya SL, Hume KR, Balkman CE. A retrospective study of proteinuria in dogs receiving toceranib phosphate. *Can Vet J*. 2018 Jun;59(6):611-616. PMID: 29910474; PMCID: PMC5949950.
14. Isotani M, Tamura K, Yagihara H, et al. Identification of a c-kit exon 8 internal tandem duplication in a feline mast cell tumor case and its favorable response to the tyrosine kinase inhibitor imatinib mesylate. *Vet Immunol Immunopathol* 2006;114:168-172. Epub September 5, 2006.
15. Isotani M, Yamada O, Lachowicz JL, et al. Mutation in the fifth immunoglobulin-like domain of kit are common and potentially sensitive to imatinib mesylate in feline mast cell tumours. *Br J Haematol* 2009;148:144-153.
16. Dubreuil P, Letard S, Ciufolini M, et al. Masitinib (AB1010) a potent and selective tyrosine kinase inhibitor targeting KIT. *PLoS ONE* 2009;4(9):e7258. Doi: 10.1371/journal.pone.0007258.
17. Daly M, Sheppard S, Cohen N, Nabity M, Moussy A, Hermine O, Wilson H. Safety of masitinib mesylate in healthy cats. *J Vet Intern Med*. 2011 Mar-Apr;25(2):297-302. doi: 10.1111/j.1939-1676.2011.0687.x. Epub 2011 Feb 11. PMID: 21314730.
18. Hahn KA, Ogilvie G, Rusks T, et al. Masitinib is safe and effective for the treatment of canine mast cell tumors. *J Vet Intern Med* 2008;22:1301-1309.
19. Gentilini F. Letter to the editor: "Masitinib is safe and effective for the treatment of canine mast cell tumors" *J Vet Intern Med*. 2010;24:6. author reply 7.
20. Totzeck M, Mincu RI, Mrotzek S, Schadendorf D, Rassaf T. Cardiovascular diseases in patients receiving small molecules with anti-vascular endothelial growth factor activity: a meta-analysis of approximately 29,000 cancer patients. *Eur J Prev Cardiol* 2018;25:482-94.
21. Abdel-Qadir H, Ethier JL, Lee DS, Thavendiranathan P, Amir E. Cardiovascular toxicity of angiogenesis inhibitors in treatment of malignancy: a systematic review and meta-analysis. *Cancer Treat Rev* 2017;53:120-7.
22. Herrmann, J.; Yang, E.H.; Iliescu, C.A.; Cilingiroglu, M.; Charitakis, K.; Hakeem, A.; Toutouzas, K.; Leesar, M.A.; Grines, C.L.; Marmagkiolis, K. Vascular toxicities of cancer therapies: The old and the new—An evolving avenue. *Circulation* 2016, 133, 1272-1289.
23. Ye JZ, Hansen FB, Mills RW, Lundby A. Oncotherapeutic Protein Kinase Inhibitors Associated With Pro-Arrhythmic Liability. *JACC CardioOncol*. 2021 Mar 16;3(1):88-97. doi: 10.1016/j.jacc.2021.01.009. PMID: 34396309; PMCID: PMC8352262.
24. Kerkela, R.; Grazette, L.; Yacobi, R.; Iliescu, C.; Patten, R.; Beahm, C.; Walters, B.; Shevtsov, S.; Pesant, S.; Clubb, F.J.; Rosenzweig, A.; Salomon, R.N.; Van Etten, R.A.; Alroy, J.; Durand, J.B.; Force, T. Cardiotoxicity of the cancer therapeutic agent imatinib mesylate. *Nat. Med.*, 2006, 12, 908-916.
25. Novo G, Di Lisi D, Bronte E, Macaione F, Accurso V, Badalamenti G, Rinaldi G, Siragusa S, Novo S, Russo A. Cardiovascular Toxicity in Cancer Patients Treated with Tyrosine Kinase Inhibitors: A Real-World Single-Center Experience. *Oncology*. 2020;98(7):445-451. doi: 10.1159/000505486. Epub 2020 Apr 29. PMID: 32348984.
26. Chung, R.; Tyebally, S.; Chen, D.; Kapil, V.; Walker, J.M.; Addison, D.; Ismail-Khan, R.; Guha, A.; Ghosh, A.K. Hypertensive Cardiotoxicity in Cancer Treatment—Systematic Analysis of Adjuvant, Conventional Chemotherapy, and Novel Therapies—Epidemiology, Incidence, and Pathophysiology. *J. Clin. Med*. 2020, 9, 3346. [
27. Waliyani S, Sainani KL, Park LS, Zhang CA, Srinivas S, Witteles RM. Increase in Blood Pressure Associated With Tyrosine Kinase Inhibitors Targeting Vascular Endothelial Growth Factor. *JACC CardioOncol*. 2019 Sep 24;1(1):24-36. doi: 10.1016/j.jacc.2019.08.012. PMID: 34396159; PMCID: PMC8352203.
28. Hartmann JT, Haap M, Kopp HG, Lipp HP. Tyrosine kinase inhibitors - a review on pharmacology, metabolism and side effects. *Curr Drug Metab*. 2009 Jun;10(5):470-81. doi: 10.2174/138920009788897975. PMID: 19689244.
29. Rosti, G.; Martinelli, G.; Baccarani, M. In reply to 'Cardiotoxicity of the cancer therapeutic agent imatinib mesylate'. *Nat. Med.*, 2007, 13, 15-16.
30. Alpers, C. E., Seifert, R. A., Hudkins, K. L., et al. (1993) PDGF-receptor localizes to mesangial, parietal epithelial, and interstitial cells in human and primate kidneys. *Kidney International* 43, 286-294
31. Miliaras, D., Karasavvidou, F., Papanikolaou, A., et al. (2004) KIT expression in fetal, normal adult, and neoplastic renal tissues. *Journal of Clinical Pathology* 57, 463-466
32. Kuijlaars M, Helm J, McBrearty A. Development and progression of proteinuria in dogs treated with masitinib for neoplasia: 28 cases (2010-2019). *J Small Anim Pract*. 2021 Aug;62(8):646-654. doi: 10.1111/jsap.13305. Epub 2021 Feb 25. PMID: 33634470.
33. Sum, S. O., Hensel, P., Rios, L., et al. (2010) Drug-induced minimal change nephropathy in a dog. *Journal of Veterinary Internal Medicine* 24, 431-435.
34. Brown MR, Cianciolo RE, Nabity MB, Brown CA, Clubb FJ, Lees GE; Masitinib-associated minimal change disease with acute tubular necrosis resulting in acute kidney injury in a dog. *J Vet Intern Med*. 2013 Nov-Dec; 27(6):1622-6.
35. Chu, T. F., Rupnick, M. A., Kerkela, R., et al. (2007) Cardiotoxicity associated with tyrosine kinase inhibitor sunitinib. *Lancet* 370, 2011-2019
36. Azizi, M., Chedid, A. & Oudard, S. (2008) Home blood-pressure monitoring in patients receiving sunitinib. *New England Journal of Medicine* 358, 95-97
37. Shreenivas S, Oparil S. The role of endothelin-1 in human hypertension. *Clin Hemorheol Microcirc*. 2007;37(1-2):157-78. PMID: 17641406.
38. T. Pizoń, M. Rajzer, T. Kameczura. The role of the renin-angiotensin-aldosterone system in etiology and pathogenesis of arterial hypertension and its systemic complications — what remains from Laragh and Alderman idea?; *Arterial Hypertension* 2011, vol. 15, no 6, pages 371-382
39. Laragh JH. Laragh lesson in renin system pathophysiology for treating hypertension and its fatal cardiovascular consequences. *Elsevier* 2002.
40. Klosterman ES, Pressler BM. Nephrotic syndrome in dogs: Clinical features and evidence-based treatment considerations. *Top Companion Anim Med*. 2011;26:135-142.
41. Sapieryński R, Jankowska U, Jagielski D, Klczkowska-Klarowicz K. Large granular lymphoma in six cats. *Pol J Vet Sci*. 2015;18(1):163-9. doi: 10.1515/pjvs-2015-0021. PMID: 25928924.
42. Lawrence J, Saba C, Gogal R Jr, Lamberth O, Vandenplas ML, Hurlley DJ, Dubreuil P, Hermine O, Dobbins K, Turek M. Masitinib demonstrates anti-proliferative and pro-apoptotic activity in primary and metastatic feline injection-site sarcoma cells. *Vet Comp Oncol*. 2012 Jun;10(2):143-54. doi: 10.1111/j.1476-5829.2011.00291.x. Epub 2011 Aug 25. PMID: 22236016.
43. Wiles V, Hohenhaus A, Lamb K, Zaidi B, Camps-Palau M, Leibman N. Retrospective evaluation of toceranib phosphate (Palladia) in cats with oral squamous cell carcinoma. *J Feline Med Surg*. 2017 Feb;19(2):185-193. doi: 10.1177/1098612X15622237. Epub 2016 Jul 9. PMID: 26755491.
44. Berger EP, Johannes CM, Post GS, Rothchild G, Shiu KB, Wetzel S, Fox LE. Retrospective evaluation of toceranib phosphate (Palladia) use in cats with mast cell neoplasia. *J Feline Med Surg*. 2018 Feb;20(2):95-102. doi: 10.1177/1098612X17695898. Epub 2017 Mar 1. PMID: 29172873.
45. Todd JE, Nguyen SM. Long-term survival in a cat with pancreatic adenocarcinoma treated with surgical resection and toceranib phosphate. *JFMS Open Rep*. 2020 Jun 12;6(1):2055116920924911. doi: 10.1177/2055116920924911. PMID: 32587749; PMCID: PMC7294497.
46. Holtermann, N., Kiupel, M., & Hirschberger, J. (2016). The tyrosine kinase inhibitor toceranib in feline injection-site sarcoma: efficacy and side effects. *Veterinary and Comparative Oncology*, 15(2), 632-640. doi:10.1111/vco.12207
47. Harper A, Blackwood L. Toxicity and response in cats with neoplasia treated with toceranib phosphate. *J Feline Med Surg*. 2017 Jun;19(6):619-623. doi: 10.1177/1098612X16643124. Epub 2016 Apr 18. PMID: 27090289.
48. Atallah, E.; Kantarjian, H.; Cortes, J. In reply to 'Cardiotoxicity of the cancer therapeutic agent imatinib mesylate'. *Nat. Med.*, 2007, 13, 14-16
49. The Criteria Committee of the New York Heart Association. (1994). *Nomenclature and Criteria for Diagnosis of Diseases of the Heart and Great Vessels* (9th ed.). Boston: Little, Brown & Co. pp. 253-256
50. Smrkovski OA, Essick L, Rohrbach BW, Legendre AM. Masitinib mesylate for metastatic and non-resectable canine cutaneous mast cell tumours. *Vet Comp Oncol* 2015;13:314-321.
51. Pellin MA, Wouda RM, Robinson K, Tsimbas K, Kurzman ID, Biller BJ, Vail DM. Safety evaluation of combination doxorubicin and toceranib phosphate (Palladia®) in tumour bearing dogs: a phase I dose-finding study. *Vet Comp Oncol*. 2017 Sep;15(3):919-931. doi: 10.1111/vco.12232. Epub 2016 May 5. PMID: 27146577.



# Heartworm disease: a severe disease of dogs and cats



Prof. **Łukasz Adaszek** DVM, PhD, DVSc, **Łukasz Mazurek** DVM  
Chair of Epizootiology and Clinic of Infectious Diseases  
Department of Veterinary Medicine of University of Life Sciences in Lublin

## Introduction

The term heartworm disease applies to a group of transmission diseases caused by parasites from the genus *Dirofilaria* including such species as *D. immitis* and *D. (Nochtiella) repens*. Both pathogens differ in terms of biology and virulence. *Dirofilaria immitis* is an etiological factor of canine and feline heartworm disease, which represents a serious health problem in animals (1, 2, 3). A mosquito which transfers the nematodes (females from the genus *Culicidae*) may infect people; however, in the human body, *Dirofilaria immitis* is unable to develop into the adult form and does not reach the heart (4, 5, 6). In small animals, *Dirofilaria repens* causes lesions in the subcutaneous tissue and is an etiological factor of cutaneous dirofilariasis in people (7, 8).

1. A mosquito sucks blood from the infected animal, and the blood contains microfilariae, namely small, long, and thin the L1 larval stage of the nematodes which circulate freely in the peripheral blood. In the gastrointestinal tract, the L1 stage transforms into L2 (8–10 DPO, days post infestation) and then into L3 after the subsequent 3 days.
2. The ambient temperature is a factor determining the L3 development. The development of invasive larval stages at 28–30°C lasts 8–10 days, 11–12 days at 24°C, and 16–20 days at 22°C. When the temperature drops below 14°C, larval development ceases.
3. Upon sucking the blood, mosquitos introduce the invasive L3 larval stage which penetrates the skin of the host.
4. The larvae mature in the muscular tissue or the abdominal cavity of the host for 75–120 days after the infestation, and meanwhile, they grow to about 25 mm. Then, they reach the circulation and migrate into the pulmonary artery and the right ventricle where they reach sexual maturity. Adult females are 25–30 cm long, and males are about 1/3 shorter.
5. Adult parasites live about 7 years and they reproduce releasing the L1 larvae into the circulation. Microfilariae can circulate in the blood for 2 years.
6. The cycle comes to an end when the

mosquito sucks the blood infested with microfilariae.

The increasing number of heartworm disease cases in animals and people over the last few years suggests a better knowledge and diagnostics of the disease on one hand, and on the other hand, it is related to the climate changes which result in the growing range of disease vectors. For the parasite to develop in the mosquito body, temperature should not fall below 14°C.

At present, heartworm disease is reported all around the world. Infestation with *D. immitis* is most often diagnosed in dogs in central Asia and southern Europe. Endemic outbreaks of the disease have been reported even in dogs in Siberia. The first case of *D. immitis* infestation in a dog from Gdynia was reported by Świątalska and Demiaszkiewicz in 2012 (9).

The area over which feline heartworm disease caused by *D. immitis* prevails corresponds with the geographic of canine heartworm disease. The infestations with these parasites have been reported in Italy and the Canary Islands as far as Europe is concerned (10, 11), whereas in Asia, the cases have been observed in Japan (12) and South Korea (13).

## Pathogenesis and clinical symptoms

The clinical symptoms of dirofilariasis are strictly related to the animal condition and the number of nematodes in the body:

- less than 25 nematodes may not cause any visible clinical symptoms
- 60 or more nematodes can disturb the heart function and damage the liver and kidneys.
- more than 100 nematodes can lead to congestion of the blood vessels and the heart (14).

## The course of *D. immitis* infestation in small animals

Canine heartworm disease caused by *D. immitis* is potentially fatal (3). It leads to progressive right ventricular insufficiency and damage to the pulmonary artery walls. The parasites located in the pulmonary vessels are associated with thickening of the endothelium (endarteritis), narrowing of

the pulmonary vessel lumen, and reduction of their elasticity. The vascular endothelium becomes more permeable, which results in albumins and blood cells penetrating the perivascular space. As a result, the muscular layer cells excessively proliferate and can migrate into the vascular lumen where together with the endothelial cells and collagen fibres, they compose the villi. The consequence of disturbed blood flow through the pulmonary vessels is fluid transudation into the lung tissue and pulmonary oedema.

At the same time, parasites which died naturally or because of the treatment can build thrombi in the blood vessels and trigger an associated inflammatory reaction.

*Dirofilaria immitis* can also damage the kidneys. Glomerulonephritis has been often observed in patients with heartworm disease (15, 16). The underlying mechanism is associated with the formation of immune complexes consisting of antibodies and larval antigens, microfilariae, or adult parasites. Protein is lost in the kidneys, and nephrosis may develop, potentially with resultant renal failure and azotaemia (17). In small dogs, a serious complication of heartworm disease is vena cava syndrome. The condition develops when the parasite clusters migrate from the lung arteries to the right heart ventricle and impair the functioning of the tricuspid valve with the resulting pressure increase in the right ventricle, the right atrium, and the vena cava and impaired blood return to the heart (18). These abnormalities can lead to death due to haemolysis, haemoglobinuria, and disseminated intravascular coagulation (DIC) (19).

Eosinophilic pneumonia is another complication associated with heartworm disease. It is caused by parasites (live or dead) located in the pulmonary vessels and infiltrations of the lung tissue with eosinophilic granulocytes, which constitute a response of the body to microfilaria antigens in the pulmonary tissue. As a result, the functioning of the pulmonary alveoli is weakened, gas exchange is disturbed, and hypoxia, hypoxaemia and severe respiratory failure develop, with accelerated and shallow breathing, cough, and dyspnoea upon presentation.

The function of each organ (the



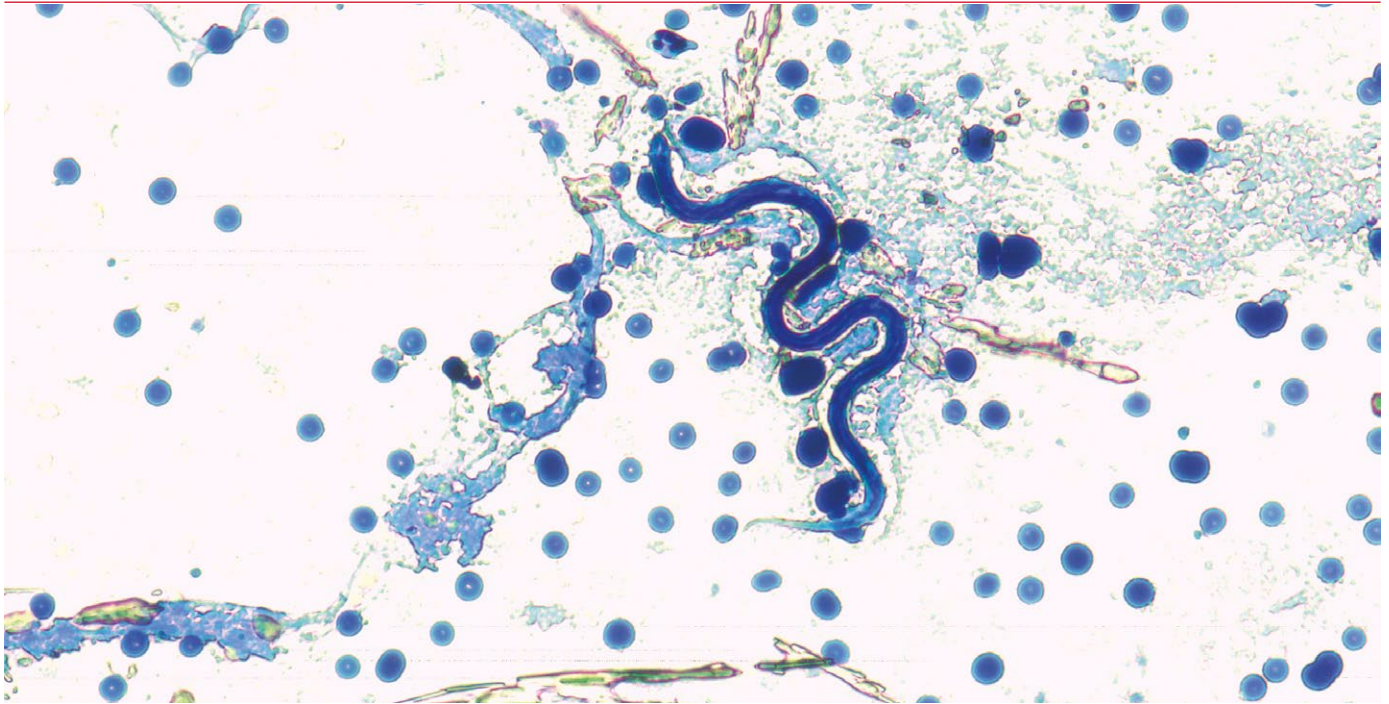

Fig. 1. Dirofilaria parasites seen in echocardiography.

brain, liver, eyes etc.) can be disturbed in heartworm disease, and subsequently, very unspecific clinical symptoms develop. Regardless of the parasites' location in the body, heartworm disease is almost always associated with cough, exercise intolerance, progressing respiratory failure, and sometimes enlargement of the spleen (8, 19).

Cats are not natural hosts of the nematode. Merely two to five parasites located in the animal heart are sufficient to induce clinical symptoms. The nematodes sometimes do not reach the heart and stop in the other organs, such as the eye, the brain or the femoral artery causing, blindness, CNS or motor disfunction, depending on the location (1, 3).

In cats, heartworm disease is usually asymptomatic. If the clinical symptoms develop, they are usually unspecific and include chronic cough, dyspnoea, or vomiting. Some infested animals suddenly die (20, 21). The typical symptoms of dirofilariasis result from the parasites being in the pulmonary vessels, with associated severe inflammation. The inflammatory response is intensified by specific macrophages that become activated in the vascular bed (22). As a result, pulmonary function is impaired, and respiratory failure develops. The symptoms associated with dirofilariasis are often misinterpreted as asthma or allergic bronchitis (8).

The development of respiratory failure, gastrointestinal problems and neurological dysfunctions are reported in a peracute form of heartworm disease (23). Dyspnoea, increased breathing rate, cough, vomiting, diarrhoea and loss of appetite are most commonly described. Ataxia, vestibular

symptoms, and blindness are less frequently seen. In animals who survive, the disease usually progresses towards a chronic stage. Chronic dirofilariasis is usually asymptomatic, but many factors can exacerbate the disease course. The affected animals demonstrate the symptoms of respiratory and gastrointestinal disorders leading to emaciation. In general, acquired heart defects do not develop in cats suffering from heartworm disease (22).

### Diagnosis

Heartworm disease is diagnosed in two stages. The first one includes a meticulous clinical examination, including additional tests, and the second stage consists of laboratory assays confirming nematode

infestation.

The blood test results are usually unspecific; regenerative anaemia, basophilia and monocytosis are reported. Eosinophilia develops in less than half of the affected animals. Pulmonary thrombosis can trigger a left-shift leucocytosis. Hyperglobulinaemia dominates in blood chemistry results (19). Imaging examinations such as X-rays, ECG, and echocardiography allow evaluation of the patient's medical state and disease severity. At an advanced disease stage, chest radiography confirms the widening of the pulmonary artery, infiltrations in the lung tissue, and enlargement of the right heart (23, 24). Following the experimental infestation of the cats, radiological changes in the lungs associated with heartworm

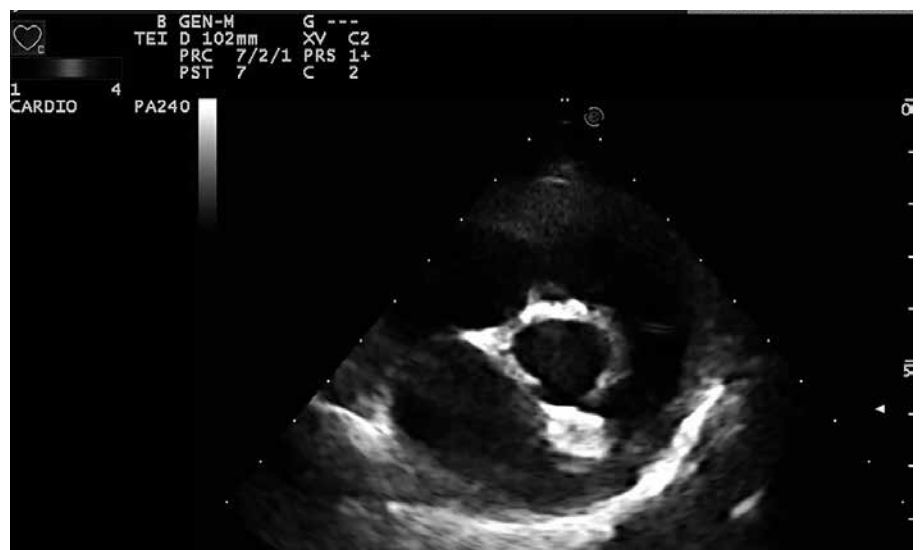


Fig. 2. Microfilaria in the canine blood.

disease have not been demonstrated until after 6 months post-infestation.

Echocardiography can demonstrate the parasites in the main pulmonary artery, and the right atrium and ventricle. They are represented as two parallel lines (25, 26) (Fig. 1). A Doppler examination allows for detecting and evaluating the severity of hypertension. In dogs at a terminal stage of disease, ECG reveals changes in the electrical axis of the heart and heart rhythm disorders (23).

Some studies have been recently performed to detect and define potential disease markers which could be used in early diagnostics of heartworm disease. The initial results have shown that troponin I and myoglobin are the markers of cardiac injury while D-dimers are a marker of thromboembolic disease (27).

Facing heartworm disease in the clinical laboratory, the simplest diagnostic method is a microscopic examination of blood smears or an analysis of a blood drop or haemolyzed blood drop. Demonstration of the parasites confirms the disease (Fig. 2).

Various types of tests can be used to diagnose dirofilariasis. Available ELISA tests detect antibodies or parasite antigens which are glycoproteins from the female reproductive tract. Antibody-detecting tests are rarely used in diagnostics due to a significant amount of false positive results, but their advantage is the possibility to use them in cats. Detection of the antigens is far more precise; specificity is almost 100%, and sensitivity exceeds 85%. However, they have not been recommended for diagnosing feline dirofilariasis (Fig. 3). Commercial tests detecting the antigens of adult stages demonstrate a higher sensitivity than the assays detecting microfilariae. The functional principle of these tests consists of immunochromatographic methods (IMC), hemagglutination (HA), and ELISA methods. They detect female nematode antigens with 100% accuracy, but they do not detect those released by the males. If a dog is infested only with male parasites, the tests can yield a false negative result.

Detection of microfilariae in the blood and a positive result of the antigen test indicate *D. immitis* infestation. Microfilariae found in the blood and a negative antigen test result suggest infestation with the other *Dirofilaria* species.

In experimental studies, dogs have been infested with 24 male parasites, the assays were performed, and the results were negative. If there are 1-2 females, the tests yield a positive result in 90%, and with 3 or more females, a positive result is obtained in 100%. Likewise, young parasites, namely less than 5 months old, are not detectable. The detectability threshold is the age of 8 months. Blood, serum, and plasma can be used with commercial tests (19).

Polymerase chain reaction (PCR) is a diagnostic assay with high specificity and sensitivity (3). Many types of PCR have been recently developed; for instance, duplex real-time PCR allows for detecting *D. immitis* and differentiating it from *D. repens* (28) while multiplex PCR enables detecting DNA of both species (29) in canine blood or mosquitos.

A cardiopulmonary form of heartworm disease is rarely diagnosed in cats because of an asymptomatic course of *D. immitis* infestation in the species. The techniques detecting parasite antigens prove most effective in dogs, but in cats, they do not necessarily allow for obtaining reliable results (30) since in this species, the infestation is associated with a small number of nematodes. Therefore, serological tests seem to have the highest diagnostic value for detecting cardiopulmonary dirofilariasis. However, these techniques

and to minimize complications (pulmonary thrombosis). Parasites are eliminated in two steps. Initially, adult nematodes are killed with melarsomine or thiacetarsamide, but it is necessary to continue the treatment to destroy microfilariae. Melarsomine (Immiticide) shows the highest efficacy in eliminating adult parasites. Unfortunately, it has a strong irritating effect and causes injection site reactions, so it is recommended to deposit the medication deep into the muscles at the L3-L5 level. The other adverse effects of melarsomine include behavioural and neurological disorders, apathy, appetite disturbance, diarrhoea, and vomiting. Overdosing can cause pulmonary oedema. Due to toxicity, the medication cannot be used in cats. The dogs from class I are administered melarsomine twice within 24 hours at a dose of 2.5 mg/kg BW, IM, each time changing the injection side. The animals included in classes II and III

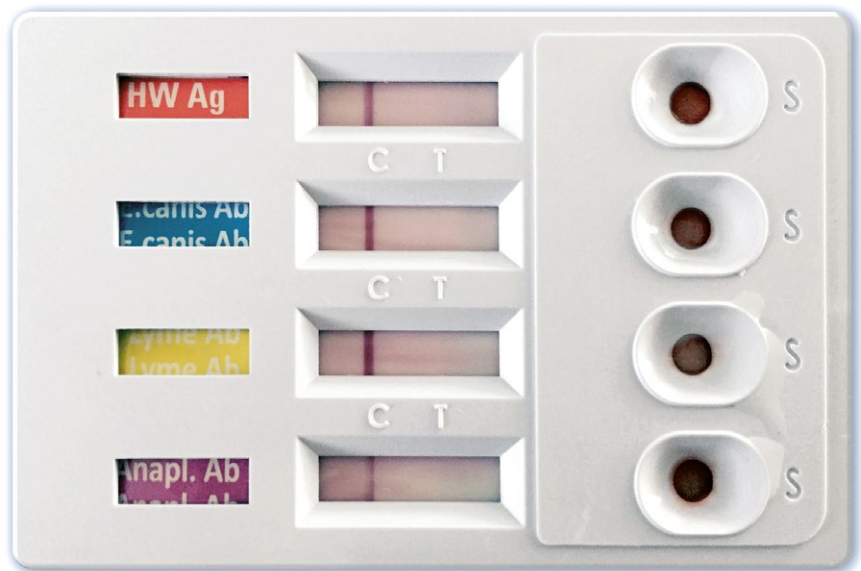


Fig. 3. Positive rapid test results for *D. immitis* and *Anaplasma phagocytophilum*.

have some disadvantages, too. It should be borne in mind that in asymptomatic animals, the antibody titres can be very low and do not indicate the infestation (31). On the other hand, in animals with clinical disease, the highest antibody titres are detected 2 months after the infestation, and therefore, serological tests are not suitable for diagnosing the early disease stages (32, 33). Nevertheless, the serological test is the most reliable, especially in combination with the other diagnostic techniques.

### Treatment and prevention

The treatment of dirofilariasis includes medications with substantial toxicity, and therefore, the protocol is selected individually for a patient and depends on the severity of the disease. The goal of the treatment is to kill both adult parasites and microfilariae

initially receive the medication at a dose of 2.5 mg/kg BW, and after one month, it is administered twice within 24 hours, as in the class I protocol.

Thiacetarsamide (Caparsolate) is another formulation used to treat dirofilariasis, and it also shows substantial toxicity. It can cause vomiting, fever, weakening, jaundice, and diarrhoea. The medication is administered in four intravenous injections (2.2 mg/kg BW) within 48 hours (extravascular injection can result in tissue necrosis). The intervals between subsequent administrations should not exceed 16 hours and be less than 6 hours. A prerequisite for successful therapy is strict adherence to the discussed protocol.

Three to four weeks after the treatment eliminating adult *Dirofilaria* stages has



been initiated, affected animals are given medications which destroy microfilariae. Ivermectin at a dose of 0.05 mg/kg BW, PO and milbemycin at a dose of 0.5-1 mg/kg BW, PO are highly effective.

An adjunctive therapy includes glucocorticoids (prednisone 1 mg/kg SID for 4 to 5 days) which control pulmonary inflammation and prevent emboli; diuretics are given to reduce oedema and exudation in the pulmonary cavity; digoxin is administered if atrial fibrillation develops; and oxygen therapy.

Surgical management is indicated for dogs with vena cava syndrome. Parasites are removed with elastic forceps introduced to the jugular vein with fluoroscopic navigation. The intraoperative mortality rate is very low, and the treatment efficacy is positively correlated with the number of evacuated parasites. Mechanical elimination of microfilariae significantly reduces the risk of pulmonary embolism. In cats, the surgical procedure is unfortunately associated with a significant risk (small diameter of the vessels, risk of damaging the tissues while removing the parasites). Accidental tearing of parasites during surgical removal can result in anaphylactic shock and death.

Symptomatic cats should receive only corticosteroids to alleviate the symptoms. In general, prednisolone is effective, with a progressive reduction of the dose. It is initially administered at a dose of 1-2 mg/kg every 12 to 24 hours, and then, 0.5 mg/kg is given every 2 days for 2 weeks. If the symptoms relapse, the treatment should be repeated.

Prevention plays an important role in restricting the spread of heartworm disease. The core of disease prevention is to avoid introducing animals into the parasite endemic areas (and to use mosquito repellents). Prevention-wise, medications should be introduced one month before the mosquito activity season and withdrawn one month after the end of the season. In endemic areas, preventive measures should be applied every month and all year round. The most popular products used in the prevention of canine dirofilariasis include selamectin at a dose of 6-12 mg/kg BW applied on the skin, ivermectin at a dose of 0.006-0.012 mg/kg BW, PO once a month and 0.024 mg/kg BW, PO, and milbemycin at a dose of 0.5-1.0 mg/kg BW, PO once a month (19). For cats (from the age of 8 weeks onward), the doses of the medications used at 30-day intervals are as follows: ivermectin 24 µg/kg, milbemycin oxime 2 mg/kg, moxidectin 1 mg/kg, and selamectin 6-12 mg/kg.

For early detection of the infestation and enhanced treatment efficacy, it is also indicated to perform periodical tests for heartworm disease in dogs and cats. Today, no vaccines against the disease are available.

Although heartworm disease seems to be exotic, some epidemiological data has demonstrated that global warming contributes to an increasing number of heartworm disease cases reported in the areas which used to be free of the disease. Therefore, it is expected that in Poland, the prevalence of heartworm disease in small animals will increase. Importantly, knowing the nature of the disease, diagnostic methods and treatment protocols are essential to manage and eliminate heartworm disease.

References:


- Greene C.E.: Infectious diseases of the dog and cat. Saunders Elsevier Inc. 2006.
- Hoch H., Strickland K.: Canine and feline dirofilariasis: life cycle, pathophysiology, and diagnosis. *Compend. Contin. Educ. Vet.* 2008, 30, 133-140.
- McCall J.W., Genchi C., Kramer L.H., Guerrero J., Venco L.: Heartworm disease in animals and humans. *Adv. Parasitol.* 2008, 66, 193-285.
- Kadłubowski R.: *Zarys parazytologii lekarskiej.* PZWL. Warszawa 1983.
- Bannister B.A., Bergg N.T., Gillespie S.H.: *Choroby zakaźne.* Wydawnictwo Medyczne Urban & Partner. Wrocław 1998.
- Sedlak K., Tomsickova M.: *Niebezpieczne infekcje odzwierzęce.* Bellona. Warszawa 2007.
- Pampiglione S., CanestriTrotti G., Rivasi F.: Human dirofilariasis due to *Dirofilaria (Nochtiella) repens*: a review of world literature. *Parassitologia* 1995, 37, 149-193.
- Simón F., López-Belmonte J., Marcos-Atxutegi C., Morchón R., Martín-Pacho J.R. What is happening outside North America regarding human dirofilariasis? *Vet. Parasitol.* 2005, 133, 181-189.
- Świątańska A., Demiaszkiewicz A.: Pierwszy w Polsce rodzimy przypadek inwazji nicieni *Dirofilaria immitis* u psa. *Życie Wet.* 2012, 87, 685-686.
- Kramer L., Genchi C.: Feline heartworm infection: serological survey of asymptomatic cats living in northern Italy. *Vet. Parasitol.* 2002, 104, 43-50.
- Morchón R.: Specific IgG antibody response against antigens of *Dirofilaria immitis* and its *Wolbachia* endosymbiont bacterium in cats with natural and experimental infections. *Vet. Parasitol.* 2004, 125, 313-321.
- Fujinami F., Tanaka H., Ohshima S.: Prevalence of protozoans helminths among cats purchased for experimental use in the Kanto Area. *JikkenDobutsu.* 1983, 32, 133-137.
- Liu J.: Serological and molecular survey of *Dirofilaria immitis* infection in stray cats in Gyeonggi province, South Korea. *Vet. Parasitol.* 2005, 130, 125-129.
- Ziętek J., Adaszek Ł., Winiarczyk S., Kutrzuba J.: *Choroby tropikalne psów i kotów.* Weter. Prakt. 2008, 5, 8-12.
- Klei T.R., Crowell W.A., Thompson P.E.: Ultrastructural glomerular changes associated with filariasis. *Am. J. Trop. Med. Hyg.* 1974, 23, 608-618.
- Ludders J.W., Grauer G.F., Dubielzig R.R., Ribble G.A., Wilson J.W.: Renal microcirculatory and correlated histologic changes associated with dirofilariasis in dogs. *Am. J. Vet. Res.* 1988, 49, 826-830.
- Paes-de-Almeida E.C., Ferreira A.M.R., Labarthe N.V., Caldas M.L.R., McCall J.W.: Kidney ultrastructural lesions in dogs experimentally infected with *Dirofilaria immitis* (Leidy, 1856). *Vet. Parasitol.* 2003, 113, 157-168.

- Furlanello T., Caldin M., Vezzoni A., Venco L., Kitagawa H.: *Patogenesi.* W: Genchi C., Venco L., Vezzoni A. *La filariosi cardiopulmonare del cane e del gatto.* Editorial Scivac, Cremona, Italy. 1998, s. 31-46.
- Niziołek R., Rutkowska K.: *Dirofilarioza u psów i kotów.* *Życie Wet.* 2009, 84, 798-805.
- Atkins C.E., Litster A.L.: *Heartworm disease.* W: August J.R. *Consultations in feline internal medicine.* Elsevier-Saunders, Philadelphia, PA. 2006, s. 323-330.
- Litster A.L., Atwell R.B.: Feline heartworm disease: a clinical review. *J. Feline Med. Surg.* 2008, 10, 137-144.
- Dillon A.R., Warner A.E., Molina R.M.: Pulmonary parenchymal changes in dogs and cats after experimental transplantation of dead *Dirofilaria immitis*. W: Soll M.D. *Proceedings of the Heartworm Symposium '92.* American Heartworm Society, Batavia, IL. 1995, s. 97-101.
- Venco L.: *Approccio diagnostico alla filariosi cardiopulmonare felina.* W: *Atti del 30th Congresso di Medicina Felina.* Editorial Scivac, Cremona, Italy. 1996, s. 89-97.
- Vezzoni A., Venco L.: *Aspetti radiografici.* W: Genchi C., Venco L., Vezzoni A. *La filariosi cardiopulmonare del cane e del gatto.* Editorial Scivac, Cremona, Italy. 1998, s. 198.
- Badertscher R.R., Losonsky J.M., Paul A.J., Kneller S.K.: Two-dimensional echocardiography for diagnosis of dirofilariasis in nine dogs. *J. Am. Vet. Med. Assoc.* 1988, 7, 843-846.
- Moise N.S.: *Echocardiography.* W: Fox P.R. *Canine and feline cardiology.* Churchill Livingstone Inc., New York, NY. 1988, s. 113-156.
- Carretón E., Corbera J.A., Juste M.C., Morchón R., Simón F., Montoya-Alonso J.A.: *Dirofilaria immitis* infection in dogs: cardiopulmonary biomarker levels. *Vet. Parasitol.* 2011, 176, 313-316.
- Latrofa M.S., Dantas-Torres F., Annoscia G., Genchi M., Traversa D., Otranto D.: A duplex real-time polymerase chain reaction assay for the detection of and differentiation between *Dirofilaria immitis* and *Dirofilaria repens* in dogs and mosquitoes. *Vet. Parasitol.* 2012a, 185, 181-185.
- Latrofa M.S., Weigl S., Dantas-Torres F., Annoscia G., Traversa D., Brianti E., Otranto D.: A multiplex PCR for the simultaneous detection of species of filarioids infesting dogs. *Acta Trop.* 2012b, 122, 150-154.
- Di Sacco B.: *Valutazioni comparative e problema nell'uso di diversi kit diagnostici per la filariosi.* *Veterinaria* 1993, 7, 69-74.
- Nelson C.T. et al. 2007. Guidelines for the diagnosis, treatment and prevention of heartworm (*Dirofilaria immitis*) in cats. *American Heartworm Society, Wilmington, DE:* <http://www.heartwormsociety.org/>
- Prieto G., Ceciliani F., Venco L., Morchón R., Simón F.: Feline dirofilariasis: antibody response to antigenic fractions containing specific 20 to 30 kDa polypeptides from the adult *Dirofilaria immitis* somatic antigen. *Vet. Parasitol.* 2002, 103, 341-353.
- Prieto G., Simón F., Genchi C., McCall J.W., Venco L.: Utility of adult antigens of *Dirofilaria immitis* for the early detection of dirofilariasis and for the evaluation of chemoprophylactic treatment in experimentally infected cats. *Vet. Parasitol.* 1999, 86, 5-1.





# Diet-associated dilated cardiomyopathy



**Justyn Gach** DVM

**Marcin Michałek** MVD, PhD

**Piotr Frydrychowski** MVD

Prof. **Agnieszka Noszczyk-Nowak** DVM, PhD, DVSc

Chair of Internal Diseases with the Clinic of Horses, Dogs and Cats, Department of Veterinary Medicine, University of Life Sciences in Wrocław

## Introduction

Dilated cardiomyopathy (DCM) is one of the most common heart diseases in dogs and affects mainly big and giant canine breeds. The breeds predisposed to DCM include Dobermans, Newfoundland, Great Danes, Cocker Spaniels, and Irish Wolfhound. The disease involves dilation of the left ventricle lumen and disturbed cardiac contractility, commonly leading to heart failure and sudden death [1].

In July 2018, the Food and Drug Administration (FDA) started an investigation into the case reports on dilated cardiomyopathy in dogs fed on certain types of animal food [2]. The diets were grain-free and contained a high level of peas, lentils, and other legume seeds and various formulations of potatoes. The reports concerned the canine breeds which had never been suspected of a genetic predisposition for dilated cardiomyopathy, such as Golden Retrievers, Labrador Retrievers, Pitbull, or German Shepherd.

## Characteristics of genetics- and diet-associated dilated cardiomyopathy

As mentioned above, there are many canine breeds which are genetically predisposed to dilated cardiomyopathy. The mean age of dogs diagnosed with DCM is usually 5-7 years, although, in some dogs, the disease develops as early as the age of 2 [1]. Such tendencies have not been so far reported for diet-associated cardiomyopathies.

Genetics-associated DCM is a progressive disease characterized by short survival time. Many studies have proven that dogs with diet-associated DCM have demonstrated a significant improvement in the echocardiographic parameters and longer survival time following a change of diet and the implementation of medical treatment. In other words, when the diet is a cause, it could also be a solution [3].

## Dilated cardiomyopathy associated with taurine deficiency

Dilated cardiomyopathy used to be one of the most common heart diseases in cats. In 1987, a groundbreaking paper was published, and it showed that in cats, DCM was associated with taurine deficiency and might be reversed with taurine supplementation [4]. Since then, cat foods have been enriched with adequate amounts of taurine, and today, feline taurine deficiency-associated DCM is a rare condition. Few cases are associated with home diets or commercial diets based on the formulas which have been developed without adequate nutritional knowledge or quality control.

However, the canine scenario is different. In 1995, veterinary cardiologists investigating the role of taurine deficiency in DCM-affected dogs suggested that some breeds (e.g., Golden Retriever or American Cocker Spaniel) could be predisposed to taurine deficiency [5]. Subsequent studies have demonstrated that taurine supplementation can partially

or completely reverse the course of the disease. Certain types of diets, i.e., low-protein or high-fibre food containing lamb and rice, have been associated with taurine deficiency in some dogs. The studies have suggested that the other dietary components (e.g., beetroot pulp) can also increase the risk of taurine deficiency, although the role of these ingredients is still unclear.

Today, it is considered that Golden Retrievers are the most susceptible breed to DCM associated with taurine deficiency. In 2018, a study was conducted with 24 dogs of this breed with a confirmed echocardiographic phenotype of dilated cardiomyopathy and a low taurine concentration in plasma or whole blood [6]. A modification of the diet and taurine supplementation resulted in a significant improvement of echocardiographic parameters in 23 dogs. Furthermore, heart failure developed in nine dogs; in some of them, the symptoms resolved without the need for further treatment, and in a few of them, it was possible to substantially reduce the doses of diuretics. Importantly, all dogs were fed a boutique, exotic-ingredient and grain-free (BEG) diet based on exotic ingredients and devoid of cereals.

Taurine deficiency seems to be most prevalent in Golden Retrievers in comparison with the other canine breeds. However, there have been some case reports on dogs genetically predisposed to DCM (Dobermans and Boxers) and presenting with low taurine concentrations. Therefore, it is recommended to determine the concentration of taurine in each dog with diagnosed DCM. It is still unclear which

taurine measurement (plasma or whole blood) better reflects the concentration in the canine heart, and it is thus suggested to measure the concentration of taurine in both plasma and whole blood. In Poland, laboratories offer assays for measuring taurine concentration in plasma samples, but whole blood analyses are unfortunately limited (according to the recommendations, whole blood measurements should be prioritized). Furthermore, the taurine deficiency should be addressed in dogs fed a BEG, low-protein, high-fibre, vegetarian, vegan, or home diet [7].

Some of the latest 2020 studies evaluating traditional and non-traditional diets have shown that in most dogs, taurine levels and cardiac function in echocardiography were normal. In addition, in some dogs with impaired systolic function, taurine concentration was not low. It emphasizes the complexity of the discussed topic and indicates that many factors potentially contribute to the development of DCM [8].

### Grain-free food: a possible cause of the problem

Over recent years, a potential association between grain-free (with legumes) food and the development of dilated cardiomyopathy has been reported [7]. Despite the lack of a definitive correlation between grain-free diets or their ingredients and the development of DCM, some veterinary cardiologists and scientists recommend switching dogs to canine food based on grains and without any exotic sources of protein (NC State Veterinary Hospital, 2019). On the other hand, there is not enough scientific evidence concerning diets as the cause of heart disease [7]. Accordingly, the guidelines for veterinarians have been developed, and they recommend the following diagnostic protocol for the scenario with the diagnosis of the DCM phenotype in an echocardiographic examination:

1. Measure troponin I concentration.
2. Determine the level of thyroid hormones.
3. Establish plasma taurine concentration.
4. Perform infectious-disease diagnostics (Snap 4Dx test, tick-borne diseases).
5. Run a Holter monitor test.
6. Consider changing the diet +/- supplementation of taurine/carnitine [9].

One of the studies has discussed the difference in echocardiographic results between dogs with DCM fed on grain-free diets or a grain-based diet. The echocardiographic parameters in the dogs on a grain-free diet suggested a more severe disease (the evaluation

included normalized end-systolic and end-diastolic dimensions of the left ventricle and LV sphericity index). The subsequent echocardiographic examinations performed 3 months after the diet was changed demonstrated a significant improvement. It should be noted that some of the dogs included in the study were fed on a grain-free diet manufactured by a big company with highly skilled veterinary nutritionists among the staff. It shows that it cannot be explicitly concluded that each grain-free diet will contribute to the development of dilated cardiomyopathy. The diet can be a potential cause or one of many aetiological of canine DCM. On top of that, all investigated animals (except for one dog) were supplemented with taurine (even the dogs with normal taurine levels) [10].

### What's next?

Diet-associated dilated cardiomyopathy is still an open topic with many unanswered questions. Some researchers conclude that despite the correlation between DCM and a BEG, vegetarian, vegan or home diet for dogs, the cause-and-effect relationship has not been proven, and other factors can be equally essential or more important. In August 2021, extensive research investigating the ingredients of diets was published. Many hypotheses were made, including cardiotoxicity of biochemical compounds or insufficient nutritional content of the diet. The studies also demonstrated that pea was a specific ingredient associated with DCM. However, there is no evidence confirming that it contributes to the development of DCM [3].

### Summary


Despite the intensification of scientific research on diet-associated dilated cardiomyopathy over the last few years, more and more questions have been raised about the correlation between specific dietary ingredients and the development and severity of cardiomyopathy. Nowadays, many pet owners follow trends based on nontraditional i.e., vegan, vegetarian, grain-free, home or exotic meat diets. It is also recommended to measure serum taurine concentration in animals fed on the above-mentioned diets (and in the future, to determine whole blood taurine levels, if it becomes possible).

### Literature:

1. Wess, G., Domenech, O., Dukes-McEwan, J., Häggström, J., & Gordon, S. (2017). European Society of Veterinary Cardiology screening guidelines for dilated cardiomyopathy in Doberman Pinschers. *Journal of veterinary cardiology: the official journal of the European Society of Veterinary Cardiology*, 19(5), 405-415. <https://doi.org/10.1016/j.jvc.2017.08.006>
2. FDA Investigation into Potential Link between Certain Diets and Canine Dilated Cardiomyopathy (at: <https://www.fda.gov/animal-veterinary/outbreaks-and-advisories/fda-investigation-potential-link-between-certain-diets-and-canine-dilated-cardiomyopathy>), Updated June 27, 2019
3. Smith, C. E., Parnell, L. D., Lai, C. Q., Rush, J. E., & Freeman, L. M. (2021). Investigation of diets associated with dilated cardiomyopathy in dogs using foodomics analysis. *Scientific reports*, 11(1), 15881. <https://doi.org/10.1038/s41598-021-94464-2>
4. Pion, P. D., Kittleson, M. D., Rogers, Q. R., & Morris, J. G. (1987). Myocardial failure in cats associated with low plasma taurine: a reversible cardiomyopathy. *Science (New York, N.Y.)*, 237(4816), 764-768. <https://doi.org/10.1126/science.3616607>
5. Kramer, G. A., Kittleson, M. D., Fox, P. R., Lewis, J., & Pion, P. D. (1995). Plasma taurine concentrations in normal dogs and in dogs with heart disease. *Journal of veterinary internal medicine*, 9(4), 253-258. <https://doi.org/10.1111/j.1939-1676.1995.tb01076.x>
6. Kaplan, J. L., Stern, J. A., Fascetti, A. J., Larsen, J. A., Skolnik, H., Peddle, G. D., Kienle, R. D., Waxman, A., Cocchiari, M., Gunther-Harrington, C. T., Klose, T., LaFauci, K., Lefbom, B., Machen Lamy, M., Malakoff, R., Nishimura, S., Oldach, M., Rosenthal, S., Stauthammer, C., O'Sullivan, L., ... Ontiveros, E. (2018). Taurine deficiency and dilated cardiomyopathy in golden retrievers fed commercial diets. *PLoS one*, 13(12), e0209112. <https://doi.org/10.1371/journal.pone.0209112>
7. Freeman, L. M., Stern, J. A., Fries, R., Adin, D. B., & Rush, J. E. (2018). Diet-associated dilated cardiomyopathy in dogs: what do we know? *Journal of the American Veterinary Medical Association*, 253(11), 1390-1394. <https://doi.org/10.2460/javma.253.11.1390>
8. Ontiveros, E. S., Whelchel, B. D., Yu, J., Kaplan, J. L., Sharpe, A. N., Fousse, S. L., Crofton, A. E., Fascetti, A. J., & Stern, J. A. (2020). Development of plasma and whole blood taurine reference ranges and identification of dietary features associated with taurine deficiency and dilated cardiomyopathy in golden retrievers: A prospective, observational study. *PLoS one*, 15(5), e0233206. <https://doi.org/10.1371/journal.pone.0233206>
9. McCauley, S. R., Clark, S. D., Quest, B. W., Streeter, R. M., & Oxford, E. M. (2020). Review of canine dilated cardiomyopathy in the wake of diet-associated concerns. *Journal of animal science*, 98(6), skaa155. <https://doi.org/10.1093/jas/skaa155>



# Polycythaemia Vera in the Cat: a case study and literature review



Karolina Kapturska DVM\*, \*\*

\* Wrocław University of Environmental and Life Sciences

\*\* Veterinary clinic „NEOVET” s.c. Hildebrand, Jelonek, Michalek

## Introduction

Polycythaemia vera (PV) is a rare myeloproliferative disorder resulting in the overproduction of erythrocytes, and it has been reported in cats since 1966 (1-3). In humans, JAK2 tyrosine kinase mutation plays a key role in the pathogenesis, which leads to permanent hyperactivation of haematopoiesis (4, 5). A detailed pathophysiological mechanism in cats remains unknown, although, in literature, the disease is described as an erythropoietin-independent clonal expansion of the individual stem cell from the hematopoietic line (6). An alternative theory suggests that the development of specific hypersensitivity to erythropoietin is the most probable pathophysiological mechanism rather than the presence of a mutated cell population in the bone marrow (7).

The basis for making a diagnosis of PV is a persistent increase in red blood cells,

haematocrit (HCT) and haemoglobin concentration in the red blood cell above the reference values in a non-dehydrated animal when the diseases associated with secondary hyperaemia are excluded. Some authors argue that idiopathic erythrocytosis rather than polycythaemia would be a more appropriate term since the number of the other blood cells (white cells or platelets) does not increase (8).

Polycythaemias are divided into relative and absolute forms. A relative increase in the number of red blood cells and haematocrit may result from severe dehydration or contraction of the pancreas e.g., due to acute haemorrhage. Absolute polycythaemias are divided into two subtypes: primary i.e., polycythaemia vera and secondary which is believed to depend on the increased production of erythropoietin (EPO) in response to hypoxaemia. Differential diagnostics should include congenital shunts of the heart and big vessels and chronic

severe lung and kidney diseases. The most common kidney diseases associated with the excessive production of red blood cells include neoplasms, polycystic kidney disease, amyloidosis, or pyelonephritis (9). In cats living at high altitudes, haematocrit increases, being the adaptation to reduced air oxygen levels (9-12).

In each feline patient, additional blood tests (a wide range of blood chemistry tests, measurement of erythropoietin level in the blood), chest radiography, abdominal ultrasonography, an arterial blood gases test and echocardiography are essential to determine the cause of elevated red blood cell counts. However, the measurement of erythropoietin level has a limited diagnostic value since normal results are frequently encountered in patients with polycythaemia secondary to hypoxaemia (12). In PV, clonal hypertrophy of the red blood cell line does not depend on the

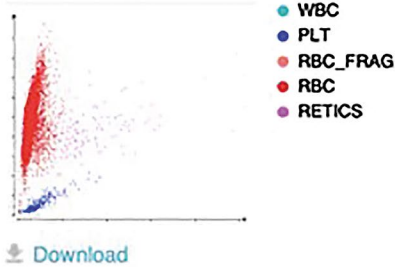
TEST	RESULT	REFERENCE VALUE		
<b>RBC</b>	<b>15.10</b>	<b>6.54 - 12.20 x10<sup>12</sup>/L</b>	H	<b>15.92</b>
<b>Haematocrit</b>	<b>* 0.777</b>	<b>0.303 - 0.523 L/L</b>	H	<b>* 0.813</b>
<b>Haemoglobin</b>	<b>230</b>	<b>98 - 162 g/L</b>	H	<b>238</b>
MCV	51.5	35.9 - 53.1 fL		51.1
MCH	15.2	11.8 - 17.3 pg		14.9
MCHC	296	281 - 358 g/L		293
<b>RDW</b>	<b>31.7</b>	<b>15.0 - 27.0 %</b>	H	<b>33.1</b>
% Reticulocyte	0.4	%		0.2
<b>Reticulocytes</b>	<b>58.9</b>	<b>3.0 - 50.0 K/<math>\mu</math>L</b>	H	<b>27.1</b>
Reticulocyte Haemoglobin	16.6	13.2 - 20.8 pg		17.0
WBC	10.11	2.87 - 17.02 x10 <sup>9</sup> /L		3.76
% Neutrophils	87.4	%		90.2
% Lymphocytes	10.1	%		5.3
% Monocytes	1.9	%		4.0
% Eosinophils	0.5	%		0.0
% Basophils	0.1	%		0.5
Neutrophils	8.84	2.30 - 10.29 x10 <sup>9</sup> /L		3.39
Lymphocytes	1.02	0.92 - 6.88 x10 <sup>9</sup> /L		0.20
Monocytes	0.19	0.05 - 0.67 x10 <sup>9</sup> /L		0.15

Fig. 1 Blood test results at the time of diagnosis.

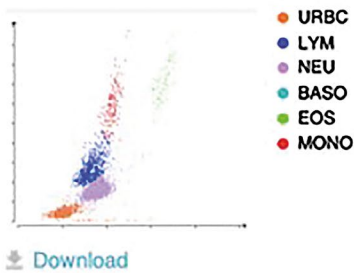


IN EXPERT'S OPINION

<b>Eosinophils</b>	<b>0.05</b>	<b>0.17 - 1.57 x10<sup>9</sup>/L</b>	L	<b>0.00</b>
Basophils	0.01	0.01 - 0.26 x10 <sup>9</sup> /L		0.02
Platelets	154	151 - 600 x10 <sup>9</sup> /L		203
MPV	16.4	11.4 - 21.6 fL		16.1
Plateletcrit	0.25	0.17 - 0.86 %		0.33



WBC Run



TEST	RESULT	REFERENCE VALUE	
<b>Glucose</b>	<b>10.74</b>	<b>4.11 - 8.84 mmol/L</b>	H
Calcium	2.05	1.95 - 2.83 mmol/L	
Sodium	163	150 - 165 mmol/L	
Potassium	4.8	3.5 - 5.8 mmol/L	
Na: K Ratio	34		
Chloride	121	112 - 129 mmol/L	
Total Protein	65	57 - 89 g/L	
Albumin	26	22 - 40 g/L	
TEST	RESULT	REFERENCE VALUE	
Globulin	39	28 - 51 g/L	
Albumin: Globulin Ratio	0.7		
Bilirubin - Total	8	0 - 15 μmol/L	

Fig. 1 Blood test results at the time of diagnosis..

**Erythropoetyna** **4.55** mU/ml 0,000-6,00

Fig. 2 The values of serum erythropoietin concentration.

concentration of erythropoietin which usually remains within the physiological range in the affected patients (13). In 2018, a team of Korean veterinarians reported a surprising case of polycythaemia in a cat; the increased EPO level resulted from pancreatic angiosarcoma, and erythrocytosis resolved after splenectomy (14). Interestingly, a biopsy of the bone marrow does not allow differentiating between primary and

secondary polycythaemia. The bone marrow cytology often confirms only hypertrophy of the red blood cell line, which is typical for myeloproliferative diseases (1, 7).

A typical clinical presentation is a few-year-old cat with seizures, brick-red mucous membranes, and without fever (8). Neurological symptoms usually develop in 50-87% of cats with PV (6, 8, 13). The underlying mechanism

probably includes hypoxia and hypoglycaemia in the ischaemic areas of the central nervous system (15). Polyuria and polydipsia, gastrointestinal symptoms (vomiting, diarrhoea), epistaxis and less specific symptoms (such as uveitis) are less commonly observed (16, 17). Most cases are diagnosed at later stages of the disease when the presented symptoms become severe (1, 8, 18-21). The advanced-stage circula-



tory disorders can lead to brain sclerotization, e.g., in the hippocampus (22).

Therapeutical possibilities are limited to periodic phlebotomies (blood removal), medicinal leech therapy (hirudotherapy), and chemotherapy with hydroxyurea (1, 20). Both hirudotherapy and regular phlebotomy can be tedious for feline patients. Chemotherapy is not recommended if pregnant women, women with small children and immunosuppressed persons share the environment with the animal (23). Recent reports have demonstrated the potential use of powdered onion as a food supplement to reduce the red blood cell count. In cats, the substances in onion induce the production of Heinz bodies, which favours the haemolysis of erythrocytes and their elimination from circulation by the red pulp macrophages in the spleen. The management can be more effective in a long-term reduction of HCT than periodic phlebotomies (18).

The prognosis for polycythaemia vera is usually good, and the average survival time is 6 years (6, 24). In human medicine, polycythaemia can progress to acute myeloid leukaemia in 3-19% of patients, and 5-14% of the patients suffer from myelofibrosis (25). Since the disease is rare, there is no data related to veterinary medicine.

### Case study

The patient was a 3-year-old, neutered, European Shorthair cat, weighing 4.5 kg. The owner reported neurological disorders presented for 48 hours (weakening of the rear legs, wobbly gait, stupor and resulting anxiety) and progressing into generalized seizures. The cat was eating and drinking and had no issues with defecation and urination.

The clinical examination demonstrated the brick-red colour of the mucous membranes in the oral cavity, the inner surface of the pinnae and the tongue. The palpable lymph nodes

were not enlarged, and the pulse was correlated with the heart rate yet slightly increased. Auscultation of the lungs and the heart did not reveal any abnormalities. The abdomen was tender, painless, and with an overfilled bladder. The pelvic paws were warm, and the pulse was well palpable on both femoral arteries. It was impossible to assess the colour of the pads due to their dark pigmentation. The blood flow was maintained which was confirmed with claw clipping.

The blood tests revealed a significant increase in the red blood cell parameters (RBC, HCT, HGB), anisocytosis (increased RDW), lymphopenia, eosinopenia, and elevated serum glucose concentration (Fig. 1). Total protein, albumins and electrolytes were within the normal range. The echocardiographic examination demonstrated a normal size of the left atrium (LA/Ao – 1.44), normal left ventricular internal end-diastolic dimension (LVIDD – 1.63 cm), a slightly increased left ventricle posterior wall thickness (LVPWd – 6.7 mm) and interventricular septum thickness at end-diastole (IVSd – 6.2 mm) with maintained contractility (FS – 43%). Blood flow through the aorta and the pulmonary artery was normal, with LVOT and RVOT being 1.2 m/s and 0.7 m/s, respectively. Free fluid was not found in the pericardial sac, thorax and abdominal cavity; any congenital defects resulting in abnormal, right-left blood flow through the heart and large vessels were not demonstrated. A bubble contrast echocardiogram (echo bubble study) was performed to confirm the standard echo results, and the outcome was also negative.

The patient suffered from bouts of vomiting about 3 months before the episode of seizures. At that time, the complete blood count (performed in another clinic) showed an increase in red blood cell parameters, and it was recommended to monitor the animal and perform a chest X-ray. The study demonstrated

a very evident vascular pattern in the lungs which might suggest hypervolemia or congenital heart defects. The heart silhouette and the image of the lungs, bronchial tree, trachea, mediastinum and the pulmonary cavity were inconspicuous. Further diagnostics were not performed.

Symptomatic management based on fluid therapy with crystalloids (125 ml of Lactated Ringer Solution BID in slow IV infusion rate) and anticoagulation therapy (clopidogrel at a dose of 18.75 mg SID) were implemented, and it was recommended to start IV infusion with diazepam at a dose of 0.5 mg/kg BW) in the case of seizure relapse. After 24 hours without any relapse of the neurological symptoms, the diagnostics were continued. The Doppler arterial BP measurement on a forelimb demonstrated normotension (systolic pressure was 110 mmHg). The abdominal ultrasound examination showed pancreatic enlargement (the body of the pancreas was up to 14 mm thick without any changes in the echo structure). The kidneys were slightly enlarged; the left (44x25 mm) and the right kidney (43x23 mm) showed moderately blurred structure, increased parenchymal echogenicity and the medullary rim sign. The small intestine lesions were typical of chronic inflammation; hypertrophy and/or infiltration of the tunica muscularis and hyperaemia/degeneration of the intestinal mucosa suggested coexisting inflammatory bowel disease (IBD). The other organs were normal. The blood smear revealed an increased density of erythrocytes, the presence of polychromatophilic cells (individual cells on the slide), mild monocytosis, degenerated and activated monocytes (about 50% of monocytes contained heavily vacuolized cytoplasm; few smudge cells and giant platelets accounting for about 30% of the platelets). The serum erythropoietin concentration was 4.55 mU/mL, namely within the reference range (0 – 6.0 mU/mL) (Fig. 2).

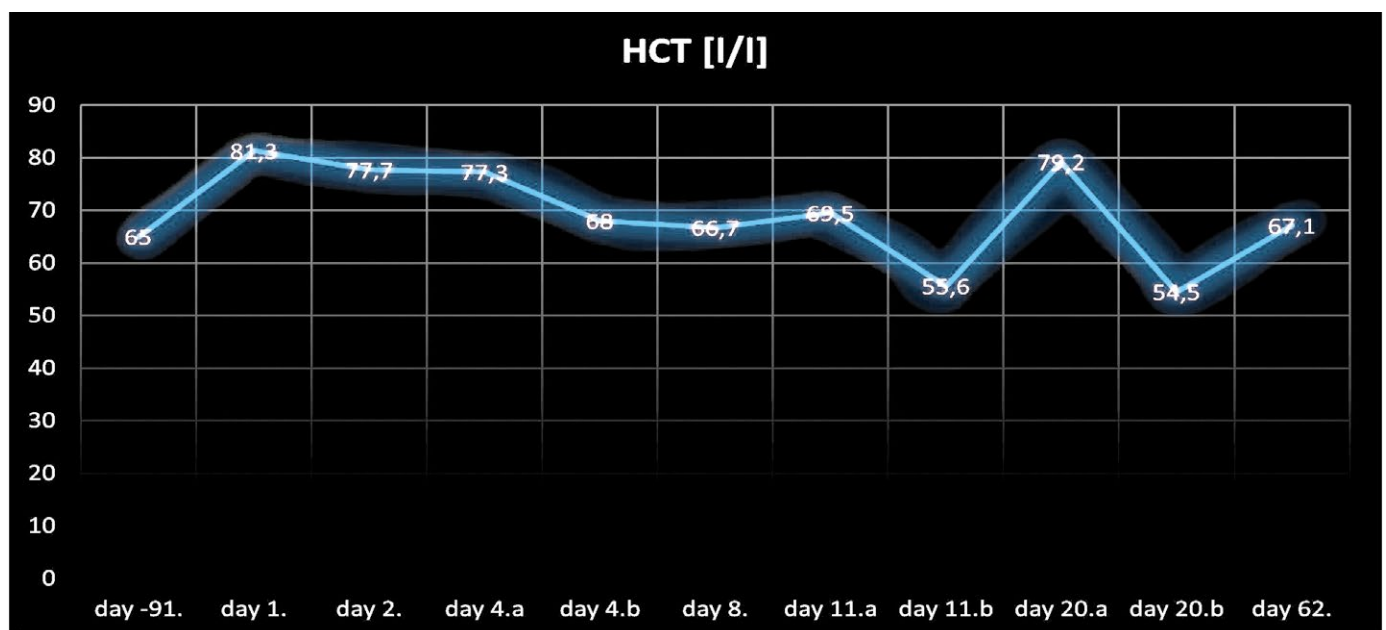


Fig. 3 Dynamics of the haematocrit values during a 22-week observation period.

To reduce the haematocrit concentration, phlebotomy was performed. Eighty-two millilitres of whole blood were removed, and 120 ml of Lactated Ringer Solution was administered at the same time, with resulting haematocrit reduction from 81.3% to 77.7%. Another phlebotomy performed after two days produced a reduction of haematocrit to 68%, and the cat developed pruritus (skin licking) and fever (temp. 40.3oC). After one week the procedure was performed for the third time and reduced haematocrit counts from 69.5% down to 55.6%. The patient was in good condition and free of alarming symptoms throughout the week, moving efficiently, eating and drinking. The pruritus resolved after a single, intramuscular injection of dexamethasone. Next, it was recommended to administer hydroxyurea (Hydroxyurea Medac) at a dose of 125 mg QOD. The fluid and anticoagulation therapy were continued. Six weeks after starting chemotherapy, haematocrit was 67.1%, and the neurological symptoms did not relapse (Fig. 3). The cat also suffered from mild gastrointestinal symptoms (change in stool consistency) which might be a side effect of chemotherapy or symptoms of concurrent IBD. Mild neutropenia and thrombocytopenia were also reported: NEU 2.21 G/L (the reference range: 3.00 – 11.00 G/L), PLT 158 G/L (the reference range: 180.0 – 550) (Fig. 4).

**Discussion**

So far, few cases of polycythaemia vera have been described in the available literature, and they usually refer to young cats (from 2 to 10 years of age, with a mean age of about 5 years), of which European Shorthair cats constitute a significant majority (87% of the cats (1, 8, 18-21). Apart from gastrointestinal disorders, the most common symptoms include neurological deficiencies such as circus movements, a change in daily habits, impaired consciousness, abnormal gait, flaccid paresis of hind legs, loss of the menace reflex (with normal spinal reflexes and normal proprioception) or even generalized or focal seizures (18-21). The owners can also notice difficulties in jumping on high furniture or scratchers and other symptoms such as laboured breathing, polyphagia, pica, polydipsia, and loss of body weight (1, 8). These symptoms frequently develop suddenly and shortly result in deteriorated general condition, which prompts their owners to look for immediate help.

In cats with PV, the mean HT value is 77.5% (from 64 to 88%) (1,8,18-21). In this discussed case, upon the first presentation, HCT was 81.3%; however, according to the owner, haematocrit had increased to 65% three months earlier. No diagnostic procedure was performed at that time, and apart from transient vomiting episodes, the patient did not present any symptoms. Due to the unspecific nature of vomiting in feline patients, the symptom was not related

Morfoloġia (oznaczenie maszynowe)				
WBC	3,62	Gł	6,00-11,0	
NEU	2,21	Gł	3,00-11,0	
NEU %	61,0	%	60,0-78,0	
LYM	1,01	Gł	1,00-4,00	
LYM %	27,9	%	15,0-38,0	
MONO	0,140	Gł	0,040-0,500	
MONO %	3,90	%	0,010-4,00	
EOS	0,260	Gł	0,040-0,600	
EOS %	7,20	%	0,010-6,00	
BASO	0,001	Gł	0,001-0,100	
BASO %	0,020	%	0,001-1,00	
RBC	14,5	Tł	5,00-10,0	
HGB	265,0	gł	90,0-150,0	
HCT	0,671	ł	0,300-0,440	
MCV	46,2	fl	40,0-55,0	
MCH	18,2	pg	13,0-16,0	
MCHC	395,0	gł	310,0-360,0	
PLT	158,0	Gł	180,0-550,0	
<b>Uwagi</b>				
Małopłytkowość w oznaczeniu maszynowym u kotów jest w zdecydowanej większości przypadków spowodowana fałszywym zanizaniem liczby płytek krwi przez obecność ich zlepów i/lub makrotrombocytów. W razie klinicznego podejrzenia trombocytopenii wskazana jest manualna weryfikacja liczby płytek krwi (badanie rozmaz skroścany lub rozmaz szeregłowy). Rutynowej weryfikacji manualnej podlegają wyniki liczby płytek krwi < 50 G/L.				
Albuminy	35,4	gł	26,0-46,0	
Białko całkowite	84,0	gł	57,0-94,0	

Fig. 4 Blood test results after 6 weeks from starting chemotherapy with hydroxyurea.

to alarming CBC results. The increase in haematocrit might have been incorrectly interpreted as the result of dehydration. In all literature cases, a simultaneous increase in haematocrit, RBC and HGB has been reported, sometimes with concomitant leucocytosis, leucopenia, lymphopenia, thrombocytopenia, or thrombocytosis (8, 18, 19). Apart from the increase in creatinine kinase (CK), blood chemistry panels do not reveal any variations from the reference ranges. The elevated CK values can result from lower perfusion caused by increased blood density and viscosity (8, 18). In polycythaemia vera cases, an arterial blood gas analysis does not show hypoxaemia (8). Serum erythropoietin concentration falls within the reference range or can be decreased (8).

Imaging investigations do not demonstrate any significant pathologies except for echocardiography which reveals mild myocardial hypertrophy even in 31% of the patients (1, 8). The pathology can be detected accidentally but it can also indicate concentric hypertrophy resulting from increased cardiac workload associated with higher blood viscosity. There is no evidence of concurrent systemic hypertension in PV-affected animals; in the discussed case, arterial BP measurements demonstrated normotension (8).

Immediate symptomatic treatment is usually necessary, e.g., controlling epileptic attacks with levetiracetam/phenobarbital or oxygen therapy before subsequent diagnostic steps (8, 21). In cats with PV, the main therapeutic objective is to reduce haematocrit and blood viscosity, which helps resolve the

neurological symptoms (21). The most effective method is immediate removal of the excessive whole blood; however, it is usually a temporary solution, and haematocrit quickly returns to the baseline values (8, 18). There are a few methods of estimating a precise quantity of blood which should be removed from the circulation. The following formula can be applied:

The K index is 0.09 for dogs and 0.07 for cats (26, 27). However, under clinical conditions, it is easier to follow the rule of removing 10-20 ml of blood per kg of body weight (26). Removing more than 20 ml of blood/kg/day is not recommended. Repeated phlebotomies are reassociated with the risk of thrombosis, thrombocythemia, hypalbuminaemia, iron deficiency, and fibrosis of the jugular vein (8, 28). Additionally, the procedure necessitates repeated anaesthesia at short intervals, which also affects the body. Phlebotomy guarantees quick resolution of the clinical symptoms but haematocrit values usually do not return to the reference range (18). In one of the studies, the mean number of phlebotomies in patients with PCV was 7, with intervals of 6.5 weeks. In one of the cats, the procedure was performed 37 times in 18 months (8).

Unfortunately, in isolated cases, blood is so dense, making standard phlebotomy impossible. In such a scenario, hirudotherapy can help, namely using a medical leech (*Hirudo medicinalis*). Leeches are placed on the properly prepared skin (shaving, cleaning) on the back, and in the kidney region (2). Disinfection agents should be avoided since it may discourage leeches from sucking (29, 30). For instance, 4 medical leeches can be

$$\text{blood volume ml} = \text{body weight} * \text{Kindex} * 1000 \frac{\text{current HTC} - \text{target HTC}}{\text{current HTC}}$$





used for a 4-kg cat. Before application of the parasites, it is advisable to puncture the skin and warm it up to create favourable conditions; however, it is not necessary (2). The other methods encouraging leeches to suck include putting a few drops of milk or sweet water directly on the skin where leeches are applied (29). Local bleeding after removal of leeches can persist for the next 24 hours. The whole procedure is not painful since natural anaesthetics in the leech saliva provide local anaesthesia of the skin (31). One leech can drink 10 ml of blood, and another 10 ml of blood flow from the application site because leeches introduce anticoagulating factors and vasodilators into the wound. The side effects of hirudotherapy include infections (with *Aeromonas hydrophila*), allergic reactions, vector-borne diseases (*Trypanosoma cruzi*), persistent excessive bleeding (for over 24 hours after the procedure), and scarring following leech bites or potential injury to the nasal or oral cavity due to uncontrollable migration of leeches (2). In human medicine, the potential transmission of HIV or hepatitis B virus is an important issue. In a clinical scenario, the pet owner can refuse the approval for the procedure due to persistent bleeding from the wounds.

If blood removal does not alleviate symptoms for at least 6 weeks, then it is necessary to start medical management (1, 32, 33). Hydroxyurea (at a dose of 10 – 45 mg/kg of body weight, PO, every 48 hours) is a medication of choice for polycythaemia in dogs, cats, and people (8). The mechanism of action consists in inhibiting the synthesis of deoxyribonucleic acid with a resulting blockage of ribonucleic reductase which is responsible for converting ribonucleotides to deoxyribonucleotides (34). Chemotherapy allows extending the intervals between blood removals or eliminates the necessity to perform phlebotomies and alleviates neurological symptoms (8). In the discussed case, the decision about medical management was taken at an early stage of the treatment due to the animal's attitude and behaviour in outpatient settings (stress, aggression, intolerance of basic medical procedures) and problem-free oral administration of medications at home.

The majority (60%) of cats managed with hydroxyurea face adverse events, including gastrointestinal symptoms, loss of hair, and methemoglobinemia, with the latter one presenting with increased respiratory rate, dyspnoea and cyanosis or mild myelosuppression (7,8). Respiratory distress due to methemoglobinemia can be addressed by using lower doses of the medication with shorter intervals. In the discussed case, six weeks after starting the treatment with hydroxyurea, mild leukopenia with thrombocytopenia developed, however, clinically insignificant. The medication has to be administered in gloves, and at home, the capsules must not be opened or divided; the veterinarian should provide the owners with relevant information (35).

Despite the recommendations to maintain the concentration of haematocrit below 50%, under practical conditions, even a small reduction hereof helps resolve the clinical symptoms (mainly seizures, stupor and motor dysfunctions) and maintain the quality of life at a satisfactory level (6, 8). The use of anticoagulating agents is not necessary; in the quoted study from 2018, only 1 of 18 patients was administered acetylsalicylic acid PO at a dose of 0.5 mg/kg of body weight every 24 hours. The FAT CAT study published in 2015 demonstrated the superiority of clopidogrel over aspirin in preventing cardiogenic arterial thromboembolism in cats (36). Therefore, clopidogrel has been used as the first-line drug in feline patients with an increased risk of intravascular coagulation.

To summarize, despite being extremely rare, feline polycythaemia vera should be a part of differential diagnostics in patients with brick-red mucous membranes and neurological symptoms. It is still a disease with unclear aetiology which can be effectively managed. Comprehensive diagnostics are extremely important to exclude the other possible causes of polycythaemia and to manage the disease effectively with the causal treatment, if possible. A long-term prognosis is good with proper management and close monitoring for potential complications. The treatment methods should be tailored on a case basis, considering that in PV, the therapeutical success does not necessarily mean the ideal blood test results but well-being and a desired quality of feline life.

#### References:

- Evans LM and Caylor KB. (1995) Polycythemia Vera in a Cat and Management with Hydroxyurea. *Journal of the American Animal Hospital Association*, 31, 424-438. <https://doi.org/10.5326/15473317-31-5-434>.
- Harvey JW. *Atlas of Veterinary Hematology: Blood and Bone Marrow of Domestic Animals*. Philadelphia, PA: W.B. Saunders; 2001.
- Groulade P and Guillon JC. (1966) Erythremic Syndrome in Cats. *Bulletin de L'Academie Verinaire de France*, 39, 127-131.
- James C, Ugo V, Le Couedic JP, et al. A unique clonal JAK2 mutation leading to constitutive signalling causes polycythaemia vera. *Nature*. 2005;434(7037):1144-1148.
- Zhao R, Xing S, Li Z, et al. Identification of an acquired JAK2 mutation in polycythemia vera. *J Biol Chem*. 2005;280(24):22788-22792.
- Giger U. Polycythemia and erythrocytosis. In: Ettinger SJ and Feldman EC (eds). *Textbook of veterinary internal medicine*. 7th ed. St Louis: Elsevier, 2010, pp 279-283.
- Foster ES and Lothrop Jr. CD. (1988) Polycythemia Vera in a Cat with Cardiac Hypertrophy. *Journal of American Veterinary Medical Association*, 192, 1736-1738.
- Darcy H, Simpson K, Gajanayake I, et al. Feline primary erythrocytosis: a multicentre case series of 18 cats. *J Feline Med Surg*. 2018;20(12):1192-1198.
- Nitsche EK. Erythrocytosis in dogs and cats: Diagnosis and management. *Comp Cont Educ Pract Vet*. 2004;14:25-34.
- Meuten DJ. *Tumors in Domestic Animals*. 5th ed. Wiley/Blackwell: Ames IA 2017.
- Greene S Withrow & MacEwen's small animal clinical oncology. *Am J Vet Res*. 2020;81(5):391-391.
- Klainbart S, Segev G, Loeb E, Melamed D, Aroch I. Resolution of renal adenocarcinoma-induced secondary inappropriate polycythemia after nephrectomy in two cats. *J Feline Med Surg*. 2008 Jul;10(3):264-8. doi: 10.1016/j.jfms.2007.11.006. Epub 2008 Feb 8. PMID: 18262454.
- Hasler A & Giger U. (1996) Serum erythropoietin values

in polycythemic cats. *Journal of the American Animal Hospital Association* 32, 294-301

- Seo KW, Hong H, An SA, Lee JK, Rebhun R. Secondary inappropriate polycythemia with splenic hemangiosarcoma in a young adult cat. *Can Vet J*. 2018 Dec;59(12):1320-1324. PMID: 30532290; PMCID: PMC6237254.
- Sarkar S and Rosenkrantz T. Neonatal polycythemia and hyperviscosity. *Semin Fetal Neonat M* 2008; 13: 248-255.
- Hasler A & Giger U. (1999) Polycythemia. In: *Textbook of Veterinary Internal Medicine*, 5th ed. Eds S.J. Ettinger and E.C. Feldman. W.B. Saunders, Philadelphia. pp 203-206
- Vail D. (1999) Hematopoietic tumors. In: *Textbook of Veterinary Internal Medicine: 5th ed*. Eds S.J. Ettinger and E. C. Feldman. W. B. Saunders, Philadelphia. pp 507-523
- Vasilatis DM, McGill JE, Gilor C. A novel bone marrow-sparing treatment for primary erythrocytosis in a cat: Onion powder. *J Vet Intern Med*. 2021 Jul;35(4):1977-1980. doi: 10.1111/jvim.16194. Epub 2021 Jun 10. PMID: 34110655; PMCID: PMC8295705.
- Beale C. (2017) Case Report on Feline Polycythemia Vera. *Open Journal of Veterinary Medicine*, 7, 1-7. <https://doi.org/10.4236/ojvm.2017.71001>
- Nett CS, Arnold P, Glaus TM. Leeching as initial treatment in a cat with polycythaemia vera. *J Small Anim Pract*. 2001;42(11):554-556.
- Fennell Charlotte (2018). Polycythaemia vera in cats: a patient care report. *The Veterinary Nurse*, 9(8), 437-441. Doi: 10.12968/vetn.2018.9.8.437.
- Kempf J, von Magnis J. Verdacht auf Hippocampusklerose bei einer Europäisch-Kurzhaarkatze mit der Diagnose Polycythaemia vera [Suspected hippocampal sclerosis in an european shorthair cat diagnosed with polycythemia vera]. *Tierarztl Prax Ausg K Kleintiere Heimtiere*. 2019 Dec;47(6):447-452. German. doi: 10.1055/a-1020-3761. Epub 2019 Dec 6. PMID: 31814093.
- Smith AN, Klahn S, Phillips B, et al. ACVIM small animal consensus statement on safe use of cytotoxic chemotherapeutics in veterinary practice. *J Vet Intern Med*. 2018;32(3):904-913.
- Ettinger SJ and Feldman EC. (2005) *Textbook of Veterinary Internal Medicine*. 6th Edition, Elsevier Inc., St. Louis.
- Scott L, Tong W, Levine R, et al. JAK2 exon 12 mutation in polycythemia vera and idiopathic erythrocytosis. *New Engl J Med* 2007; 356: 459-468.
- McDonnell J. Polycythemia. *Vet Tech*. 2012;33(10). <https://tinyurl.com/y8zlvbg2> (Accessed 19 September 2018)
- Cook SM and Lothrop Jr. CD. (1994) Serum Erythropoietin Concentrations Measured by Radioimmunoassay in Normal, Polycythemic, and Anemic Dogs and Cats. *Journal of Veterinary Internal Medicine*, 8, 18-25. <https://doi.org/10.1111/j.1939-1676.1994.tb03191.x>
- Barbui T, Passamonti F, Accorsi P, et al. Evidence- and consensus-based recommendations for phlebotomy in polycythemia vera. *Leukemia*. 2018;32(9):2077-2081.
- O'Haram M. (1988) Leeching: a modern use for an ancient remedy. *American Journal of Nursing* 08, 1656-1658
- Hoams SL. (1989) The emergency management of a medicinal leech bite. *Annals of Emergency Medicine* 18, 316-319
- Fields WS. (1991) The history of leeching and hirudin. *Haemostasis* 21, 3-10
- Peterson ME & Randolph JF. (1982) Diagnosis of canine primary polycythemia and management with hydroxyurea. *Journal of the American Medical Association* 180, 415-418
- Peterson ME. (1983) Diagnosis and treatment of polycythemia. In: *Current Veterinary Therapy VIII*. Ed R. W. Kirk. W. B. Saunders, Philadelphia. pp 406-408
- Madaan K, Kaushik D, Verma T. Hydroxyurea: a key player in cancer chemotherapy. *Expert Rev. Anticancer Ther*. 2012; 12: 19-29.
- Frimberger A, Moore A. *Safety First: Handling Chemotherapy Drugs*. Wauchope NSW: Australian Veterinary Association; n.d. <https://tinyurl.com/ydhpqpp8> (Accessed 19 September, 2018)
- Hogan DF, Fox PR, Jacob K, Keene B, Laste NJ, Rosenthal S, Sederquist K, Weng HY. Secondary prevention of cardiogenic arterial thromboembolism in the cat: The double-blind, randomized, positive-controlled feline arterial thromboembolism; clopidogrel vs. aspirin trial (FAT CAT). *J Vet Cardiol*. 2015 Dec;17 Suppl 1:S306-17. doi: 10.1016/j.jvc.2015.10.004. PMID: 26776588.

# The coughing dog: differentiating respiratory cough from cardiac cough



Theodoros Sinanis DVM, MSc, Veterinary cardiology services, Kalamata, Greece

## Introduction

Cough is a protective mechanism arising from the stimulation of cough receptors located predominantly in the larynx and larger airways such as the trachea, carina, and bronchi, whereas irritation of smaller bronchi, bronchioles, and alveoli does not elicit coughing (1) (Figure 1). Airway compression or collapse, airway inflammation and airway secretion are the three main cough-stimulating factors (2 – 3). The nature of cough can be determined by evaluating certain history data and clinical and diagnostic imaging findings; however, accurate differentiation is not always achievable. Previously, it has been thought that the heart murmur in older dogs with cardiomegaly signifies a cardiac origin of coughing, and cough has been attributed to compression of the left mainstem bronchus or congestive heart failure. However, cardiogenic pulmonary oedema should not be considered the cause of cough unless fluid accumulation is severe enough to infiltrate the upper airways. Since a respiratory disease is more commonly observed in older dogs, cardiomegaly can provoke cough in patients with a pre-existing airway disease than in young individuals with a healthy respiratory system. Whilst cough and heart disease often coexist, they are not necessarily associated, and cough can be secondary to another disease.

## Pathophysiology

Accumulation of secretions or fluid in the airways, foreign material, airway collapse or compression and the effects of inhaled irritants or inflammatory mediators typically stimulate the cough reflex (4, 6). Non-productive or dry cough can be characterized as croaking or a 'geese honk' sound. Sometimes, a cough involves a minimal amount of secretions. Common situations triggering dry cough include tracheal collapse, irritation of the tracheobronchial tree alone or in combination with main bronchus compression e.g., due to the left atrium (LA) enlargement, allergic pulmonary disease etc. Primary pulmonary oedema or heartworm disease can also provoke a non-productive cough (3).

Coughing becomes productive when several types of secretions are involved, like mucus, oedematous fluid, exudate, or blood. In most cases, dogs and cats do not expectorate these secretions in an easy-to-notice manner, so the pet owner may not observe productive coughing. In such a scenario, the latter is usually followed by swallowing. Less commonly, expectoration can occur, notably with bloody excretions. Chronic bronchitis, bronchopneumonia, bronchiectasis, pulmonary oedema, and haemoptysis are the

most common productive cough triggers (6).

Uncommon haemoptysis refers to excreting pink or bloody foam, which is usually correlated with diffuse pulmonary oedema secondary to left-sided congestive heart failure (CHF), heartworm disease, pulmonary thromboembolism, and pulmonary neoplasia. Less common causes of haemoptysis include coagulopathy, lung torsion, foreign bodies, or fungal diseases.

## Origin of cough

There are three main factors leading to the stimulation of cough receptors:

- airway compression or collapse,
- airway inflammation,
- airway secretion.

In small canine breeds, airway collapse, such as tracheal collapse, very often provokes the so-called 'geese honk' sound associated with the collapse of the thoracic tracheal section and/or the mainstem bronchi. In dogs with tracheal collapse due to limited airflow during inspiration, a characteristic 'click' or 'grunt' is produced, while the collapse of the cervical tracheal section usually evolves into inspiratory breathing difficulty. In dogs with LA enlargement associated with left-sided cardiac disease, airway compression (e.g., left mainstem bronchus) is believed to be the major cause of cough, affecting mostly smaller breeds in which the mainstem bronchi are more prone to compression (2). However, more

recent data indicates that even a very enlarged LA is unlikely to cause a cough unless the airways become irritated or collapsed (7). Primary lung tumours must be of sufficient size to compress the airways and produce coughing, yet in such patients, bacterial infections are most commonly associated with the development of cough.

Airway inflammation usually comes with chronic bronchitis–tracheobronchitis which can be of a bacterial, parasitic, or viral origin. In most cases, tracheobronchial collapse is also related to bacterial infections. To date, it has been reported that canine susceptibility to SARS-CoV-2 is limited. Dogs lack some genes encoding the inflammatory immune response that is typical of humans infected with COVID-19 (8). Therefore, while dogs can contract COVID-19 from humans, human-to-dog transmission appears extremely rare.

In patients with bacterial pneumonia or bronchopneumonia, airway secretions build up and travel to the larger airways to activate the cough receptors and provoke coughing. A small quantity of secretions or fluid (e.g., with pulmonary oedema) located in the distal alveoli may not lead to cough but if coughing is present, it is only mild since the number of cough receptors is low in the distal airways (1).

## Differentiating respiratory cough from cardiac cough

In the geriatric dog, coughing remains a diagnostic and therapeutic dilemma, yet the nature of the cough can be determined by evaluating certain history data, and clinical and diagnostic imaging findings; however, the accurate differentiation is not always feasible (Table 1).

## Medical history & patient data collection

The age, breed and history of the animal often help the clinician to differentiate between the two main causes of coughing and make a more accurate diagnosis.

The breed and size of the dog can be a useful discriminator (9 – 10). Small dogs (Yorkshire terriers, Poodles, Pomeranians, Maltese, Chihuahuas) are more likely to cough with heart disease compared to larger breeds. Furthermore, small canine breeds are also predisposed to tracheal collapse, bronchomalacia and chronic bronchitis. Though tracheal collapse occurs almost exclusively in small-breed dogs, bronchial collapse and bronchomalacia can affect any canine breed and are reported in medium-breed and large-breed dogs (11 – 12).

### Cough or not cough?

- History, observation, physical examination (tracheal palpation etc)
- Rule out reverse sneezing, vomiting

### Evidence for **pulmonary parenchymal involvement** or other concurrent disease?

### Evidence for **congestive heart failure?** (dyspnea, exercise intolerance, syncope, increased sleeping respiratory rate)

### Evaluate chest radiographs

### Select other diagnostic tests (echocardiography, bronchoscopy, CT scan)





Therefore, even large dogs with heart disease can have a mixed-origin cough. West Highland White Terriers usually suffer from idiopathic pulmonary fibrosis and present mostly with respiratory cough (13). Inspiratory coarse crackles in the absence of a heart murmur are usually the only auscultatory finding in such cases. In young dogs with a recent stay in a dog kennel and dry cough or a history of intense vomiting or regurgitation, respiratory cough is typically reported and attributed to Bordetella infection and aspiration pneumonia, respectively. Congenital or acquired oesophageal and pharyngeal abnormalities most often induce cough after eating (14).

Dogs with chronic heart disease usually suffer from mild, intermittent cough, despite being non-pathognomonic, coughing most often occurs at night or the so-called recumbency cough develops, which is usually non-productive and lower in tone. A coughing and dyspnoeic dog with pink or bloody foamy expectoration in the mouth or nose typically indicates developing pulmonary oedema due to congestive left heart failure. On the other hand, a chronic, loud, harsh, and dry cough triggered by excitement and followed by nonproductive gagging is more commonly reported in patients with large airway disease (e.g., tracheal collapse, tracheobronchitis) (10, 14). Unless airway obstruction is present, dogs with a collapsed trachea or other airway disease usually have a normal resting respiratory rate and exercise capacity between coughing episodes. Nevertheless, a coughing dog with congestive heart failure usually presents increased resting and sleeping respiratory rate (15), weight loss, weakness, and syncope (16). Obesity, heat stress and elevated humidity seem to enhance proneness to coughing in cases of airway collapse (10).

In patients with chronic airway inflammation, a productive cough in the early morning or after sleep results from the airway secretions accumulating during sleep. Cough after drinking is nonspecific and can be related to

cardiac disease, tracheal collapse, chronic tracheitis, tracheobronchitis, laryngeal problems, or other causes of dysphagia (3, 10).

### Clinical examination data

A physical examination can provide further data and etiologic clues as to the origin of the cough.

In the coughing patient, cardiac auscultation frequently reveals mild or acute murmurs. Over the previous years, it has been thought that in older dogs with cardiomegaly and without CHF, a heart murmur signifies the cardiac origin of coughing, which can be attributed to the compression of the left mainstem bronchus by the large left atrium (17 – 18). However, the role of cardiomegaly and specifically LA enlargement in airway collapse or compression remains unclear. Recent studies have failed to demonstrate an association between moderate-to-severe LA enlargement and left bronchial collapse, and therefore, airway inflammation was likely the main cause of coughing in dogs suffering from both LA enlargement and airway collapse (19) (Figure 2). Interestingly, the owners of young dogs affected with congenital cardiac abnormalities accompanied by advanced cardiomegaly have not mentioned cough as the main complaint (20). Worthy of mentioning, moderate or significant airway collapse in small breed dogs (notably obese ones) with cough can lead to decreased lung or thoracic volume. In the latter case, it happens that the clinician can have a false radiographic impression of the enlarged cardiac silhouette causing the bronchial collapse (11). Debunking the concept of cardiogenic cough, pulmonary oedema should not be an expected cause of cough, unless fluid accumulation is severe enough to invade the upper airways (bronchioles & main bronchi) and produce only a mild, moist cough (7). Instead, in those patients, an abnormal radiographic airway pattern in conjunction with LA enlargement is associated with coughing in these patients (3, 21). Previous and recent data in human patients have

suggested that the common symptoms of CHF include fatigue, dyspnoea, peripheral oedema, and exercise intolerance, whereas cough is considered a minor sign (22 – 23). Finally, the evaluation of heart rate and rhythm can sometimes help clinicians by providing further evidence. When a cardiac patient presents sinus arrhythmia or bradycardia, then cough related to mitral valve disease is very unlikely to develop, with or without cardiomegaly (2, 14).

Thoracic or lung auscultation is a significant factor that clinicians should consider when examining a coughing dog. Auscultatory wheezing tends to be more typical of respiratory than cardiac pathologies. Crackles on both inspiration and expiration are occasionally detected in dogs with bronchomalacia and small airway collapse; moreover, they can suggest mucus accumulation in the airways associated with concurrent bronchitis.

Tracheal palpation can trigger coughing in animals with tracheal collapse, but the examination can also provoke cough if the tracheal irritation has different aetiologies (6).

Pyrexia combined with coughing and tachypnoea is very suspicious of severe acute bacterial bronchopneumonia, and with supporting radiographic findings, it can be sufficient to make a presumptive diagnosis (2).

Laryngoscopy is another helpful examination that should be a part of the diagnostics in dogs with cough. The results of a recent study have indicated that approximately 20% of the dogs presenting with cough and referred for an examination were affected with a laryngeal or soft palate dysfunction (24).

### OTHER DIAGNOSTIC MODALITIES

#### Chest X-Rays

Thoracic and cervical radiography is the first line and most available diagnostic test for identifying the causes of cough, especially in cardiac patients. If a patient with a preexisting cardiac disease develops a cough, further thoracic imaging is recommended. Radiographs should be evaluated for evidence of cardiomegaly, congestive heart failure, large airway disease, lung masses, and any pleural space or vascular pathologies (6).

As the diagnostic method, radiography seems to be the fastest and easiest way to identify the location and severity of airway collapse. Sometimes, it is not sensitive enough to detect airway inflammation; however, it demonstrates evidence of a bronchial, interstitial, or alveolar pattern only in 40% of coughing dogs with mitral valve disease and bronchomalacia. The latter observation emphasizes the value of dynamic imaging studies (e.g., bronchoscopy, fluoroscopy) in detecting airway inflammation or collapse (19). Care should be taken since in a coughing dog, the radiographic features of cardiomegaly (particularly LA enlargement) can lead to a misdiagnosis of cardiogenic pulmonary oedema (Figure 3), especially if the evaluation of the pulmonary parenchyma is complicated by the expiratory phase of respiration (7, 19).

When tracheal collapse is suspected in a cardiac patient, it is recommended to evalu-

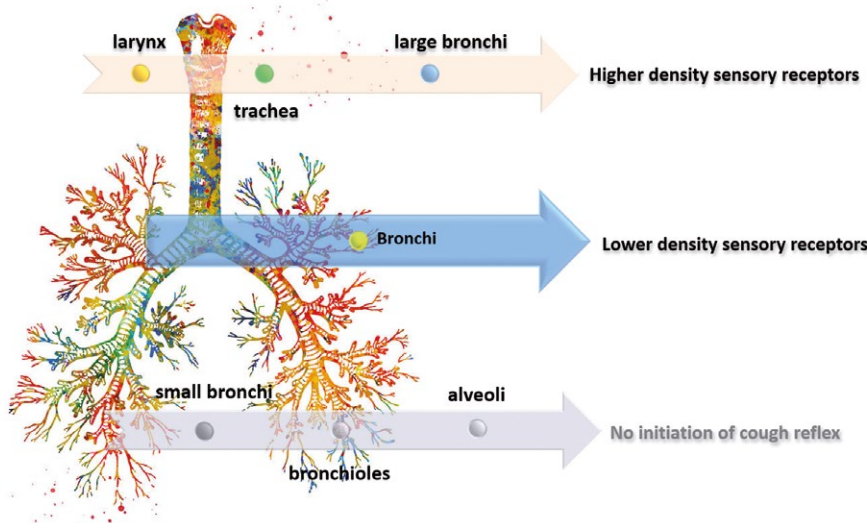


Fig. 1 Anatomical distribution of coughing receptors in the respiratory system. The proximal segments of the airways (larynx to trachea) are extremely sensitive to mechanical stimulation, while the distal parts of the airways are more chemosensitive and less mechanosensitive. Stimulation of the smaller bronchi, bronchioles and alveoli does not cause cough (Widdicombe 2001, modified).



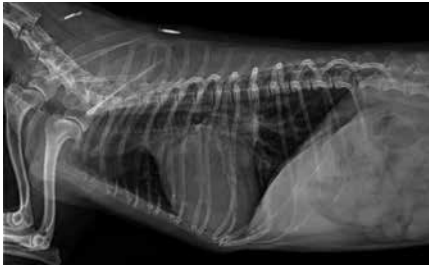


Fig. 2 A 9-year-old Maltese with mitral valve disease at B2 stage, presented with severe dry cough secondary to chronic bronchitis. The X-ray demonstrates an enhanced bronchial pattern and an increased left atrium.

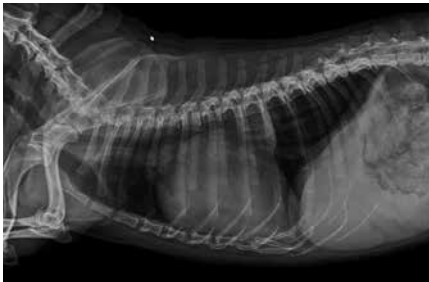

Fig. 3 Cardiomegaly and left atrial (LA) enlargement in a dog with mitral valve disease. LA enlargement can lead to a misdiagnosis of perihilar cardiogenic pulmonary oedema on expiratory chest X-rays.

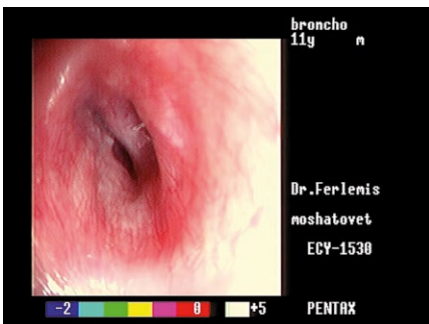


Fig. 4 The endoscopic presentation of a dog with mucosal congestion and significant bronchial collapse. BAL cytology revealed bronchoalveolar adenoma which cannot be diagnosed only with X-rays (courtesy of Dr. Ferlemis).

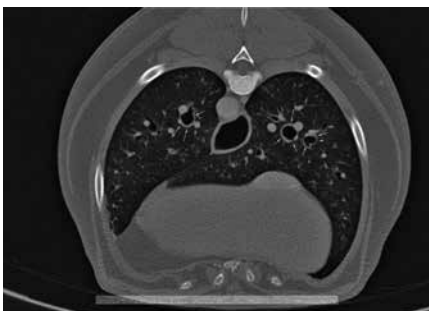


Fig. 5 Thoracic transverse CT images in a 10-year-old Labrador retriever with chronic bronchitis. There is a marked thickening of the bronchial wall.

ate lateral inspiratory and expiratory chest and cervical X-rays whereas the collapse of the cervical and intrathoracic trachea should be evident on inspiration and expiration, respectively.

### Bronchoscopy

Bronchoscopy provides useful information in dogs with airway collapse or chronic bronchitis. It is the preferred technique for evaluating and visualizing the airways since radiographs often underestimate the frequency and severity of tracheal collapse and fail to detect the collapse of the carina or bronchi (Figure 4). In humans, it is considered the method of choice for diagnosing bronchomalacia because it allows the visualization of the trachea and the mainstem, lobar or sublobar bronchi. Additionally, laryngoscopy and bronchoalveolar lavage are recommended in coughing dogs to detect concurrent infections or diseases which can impact the treatment. In dogs with left atrial enlargement and airway collapse, both neutrophilic and lymphocytic inflammation have been commonly identified. It remains unclear whether inflammation precedes or follows airway collapse.

### Echocardiography and thoracic ultrasonography

Echocardiography is the most accurate tool for diagnosing and staging most cardiac diseases. Nevertheless, as with any diagnostic test, echocardiographic findings should be evaluated considering all other evidence of disease. In any case, a normal heart scan eliminates the suspicion of any cardiac disease which can present with cough (3).

### Computed tomography (CT)

Computed tomography is a widely used modality in people with airway disease. Likewise, in the last decade, it has grown in popularity as the tool for identifying canine bronchial disease. The airway detail shown by CT scanning is much improved compared with routine thoracic radiographs (Figure 5). On the disadvantage side, CT scanning requires general anaesthesia but it can be combined with bronchoscopy and sampling for airway cytology in dogs suspected of lower airway disease (25).

### Conclusion

Considering that airway disease is more common in older dogs, cardiomegaly becomes a more likely cause of cough in patients with a pre-existing airway disease compared to young animals with healthy respiratory systems. Likewise, the owners of young dogs affected with congenital cardiac abnormalities and accompanying advanced cardiomegaly do not mention cough as a presenting complaint. The cough receptors are mainly located in the larynx and larger airways such as the trachea, carina, and bronchi, whereas the distal airways (alveoli) have less or even no cough receptors. Consequently, unless fluid accumulation is severe enough to invade the upper airways, pulmonary oedema doesn't seem to induce cough. In dogs with cardiogenic pulmonary oedema, dyspnoea or tachypnoea is always reported, which supports the fact that isolated coughing

(without dyspnoea or tachypnoea) is a very unlikely sign of CHF in dogs. Finally, cardiac cough can be defined as a cough which appears with cardiac disease yet it is not necessarily attributed to CHF. Whilst cough and heart disease often occur at the same time, they are not necessarily correlated, and cough can develop secondary to another disease.

### References:

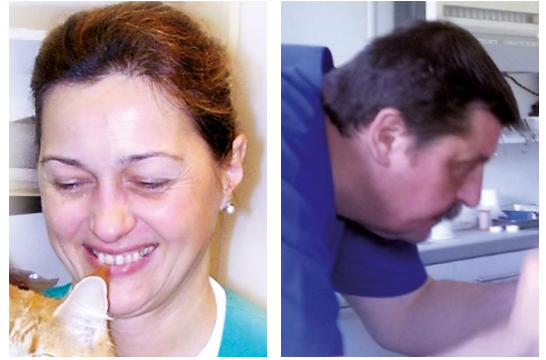- Widdicombe JG (2003) A brief overview of the mechanisms of cough. In: *Cough: Causes, Mechanisms and Therapy*, Oxford: Blackwell, pp: 17-23.
- Corcoran BM (2010) Clinical approach to coughing. In: *BSAVA manual of canine and feline cardiorespiratory medicine*, 2nd ed, BSAVA: pp 11-14.
- Ware WA (2007) Clinical manifestations and management of cardiovascular problems. Cough. In: *Cardiovascular disease in small animal medicine*, 1st ed. Manson publishing, London, pp 101-102.
- Guyton AC, Hall JE (2000) *Textbook of Medical Physiology*, 10th ed, WB Saunders, Philadelphia: pp 432-443.
- Chung KF, Pavord ID (2008) Prevalence, pathogenesis, and causes of chronic cough. *Lancet*. 371 (9621):1364-74.
- Hawkins EC (2003) Clinical manifestations of lower respiratory tract disorders. In: *Small Animal Internal Medicine*, 3rd ed. RW Nelson CG Couto eds, St. Louis, pp 250-254.
- Ferasin L, Crews L, Biller DS et al. (2013) Risk factors for coughing in dogs with naturally acquired myxomatous mitral valve disease. *J Vet Intern Med* 27(2):286-92.
- Ekstrand K, Flanagan AJ, Lin IE et al. (2021) Animal Transmission of SARS-CoV-2 and the Welfare of Animals during the COVID-19 Pandemic. *Animals (Base)* 11(7):2044.
- Macready DM, Johnson LR, Pollard RE (2007) Fluoroscopic and radiographic evaluation of tracheal collapse in 62 dogs. *J Am Vet Med Assoc* 230:1870-6.
- Maggiore AD (2020) An Update on Tracheal and Airway Collapse in Dogs. *Vet Clin North Am Small Anim Pract* 50(2):419-430.
- Johnson LR, Pollard RE (2010) Tracheal collapse and bronchomalacia in dogs: 58 cases (7/2001-1/2008). *J Vet Intern Med* 24:298-305.
- Adamama-Moraitou KK, Pardali D, Day MJ et al. (2012) Canine bronchomalacia: a clinicopathological study of 18 cases diagnosed by endoscopy. *Vet J* 191(2):261-6.
- Clercx C, Fastrès A, Roels E (2018) Idiopathic pulmonary fibrosis in West Highland white terriers: An update. *Vet J* 242:53-58
- Gompf RE (2008) The history and physical examination, coughing. In: *Manual of canine and feline cardiology*. 4th ed. Saunders Elsevier, pp. 4-5.
- Porciello F, Rishniw M, Ljungvall I et al. (2016) Sleeping and resting respiratory rates in dogs and cats with medically-controlled left-sided congestive heart failure. *Vet J* 207:164-168.
- Fox PR, Sisson D, Moisse SN (1999) Cough, Examination of the patient with cardiovascular disease. In: *Textbook of canine and feline cardiology*. 2nd ed. WB Saunders Company, pp. 43-44.
- Atkins CE (1994) Evaluation of cough in dogs with mitral valve insufficiency. *Compend Contin Educ Pract Vet* 16:1547-1552.
- Guglielmini C, Diana A, Pietra M et al. (2009) Use of the vertebral heart score in coughing dogs with chronic degenerative mitral valve disease. *J Vet Med Sci* 71:9-13.
- Singh MK, Johnson LR, Kittleson MD et al. (2012) Bronchomalacia in dogs with myxomatous mitral valve degeneration. *J Vet Intern Med* 26(2):312-9.
- Hildebrandt N, Schneider C, Schweigl T et al. (2010) Long-term follow-up after transvenous single coil embolization of patent ductus arteriosus in dogs. *J Vet Intern Med* 24:1400-1406.
- Rose RJ, Hodgson DR (2000) Protocols for common presenting complaints. In: *Manual of Equine Practice*, WB Saunders Company, Philadelphia pp 31-32.
- Watson RD, Gibbs CR, Lip GY (2000) ABC of heart failure. Clinical features and complications. *BMJ* 320:236-239.
- Ponikowski P, Voors AA, Anker SD et al. (2016) 2016 ESC guidelines for the diagnosis and treatment of acute and chronic heart failure. *European Heart Journal* 37:2129-2200.
- Johnson LR (2016) Laryngeal structure and function in dogs with cough. *J Am Vet Med Assoc* 249(2):195-201.
- Rozanski E (2020) Canine Chronic Bronchitis: An Update. *Vet Clin North Am Small Anim Pract* 50(2):393-404.



# Cardiohepatic syndrome associated with chronic heart failure in dogs

Prof. **Urszula Paśławska** DVM, PhD, DVSc, **Robert Paśławski** DVM, PhD  
 Veterinary Institute of the Faculty of Biological and Veterinary Sciences of the Nicolaus Copernicus University in Torun

**Agata Kochman** DVM, PhD  
 Department of Pathology, Monklands Hospital, Aridrie, UK



## Introduction

Heart failure is defined as the heart's inability to pump an adequate supply of blood to the tissues, namely the condition consists of insufficient tissue blood flow. At the initial stage of heart disease, the clinical symptoms are masked by the so-called compensatory mechanisms, Fig. 1.

Centralization of the circulation is one of the most basic compensatory mechanisms and is supposed to protect the vital organs such as the liver and the kidneys. The peripheral vessels become narrowed which significantly deteriorates blood supply to the skin, skeletal muscles, digestive and reproductive tract and impedes efficient blood circulation in the heart, kidneys, liver, and brain. The circulation becomes centralized thanks to the secretion of catecholamines (adrenergic activation). In long-term heart failure, the peripheral tissues suffer from ischaemia. A lack of oxygen supply (hypoxia) and nutrients as well as the accumulation of harmful metabolic products (resulting in pH decrease) contribute to improved blood circulation in the peripheral tissues, which naturally deteriorates blood supply to the vital organs.

Moreover, continuous adrenergic stimulation and activation of the renin-angiotensin-aldosterone system (RAAS) result in hypertrophy of the vascular walls, retention of fluids in the body (with resulting development of oedema), and persistent increase of the blood pressure. An adverse effect that the above-mentioned dysregulation has on the renal condition has been very well investigated and documented. The specific pathological condition is referred to as cardiorenal syndrome. It has been described both in people and domestic animals (Paśławski, Szczepankiewicz). Over the last years, more attention has been paid to a parallel pathology called cardiohepatic syndrome which involves deteriorating hepatic functions caused by heart failure. The highest number of observations is related to dogs suffering from chronic heart failure caused by degenerative valve disease (DVD). These dogs often present with symptoms which suggest the deterioration of hepatic functions such as poor coat quality, enlarged abdomen, reduced appetite (early satiety) or fluctuating appetite. The symptoms are usually mild and thus neglected by the owner or they are confused with gastro-

intestinal diseases. Dogs are usually suspected of having eaten rotten food during walks. In dogs with diagnosed heart disease, even the abnormalities in hepatic blood panels (the increased activity of aspartate aminotransferase, ASPAT, and alanine aminotransferase, ALAT, and elevated alkaline phosphatase concentration, AP) are rarely linked to heart failure.

The knowledge of pathophysiological liver dysfunction comes mainly from human medicine. The changes in the liver caused by chronic heart failure are referred to as congestive hepatopathy since they are a consequence of the reduced hepatic blood flow, specifically, a result of the increased venous pressure and reduced arterial pressure.

A decrease in the heart rate leads to a reduction of blood outflow from the large veins. The increased central venous pressure is transmitted onto the hepatic veins and results in passive hepatic hyperaemia, which disturbs oxygen and nutrients supply to hepatocytes and elimination of harmful waste products (Fig. 2).

Congestive hepatic oedema results in cholestasis, which leads to the accumulation of biliary pigments in the liver (Fig. 3, 4, 5).

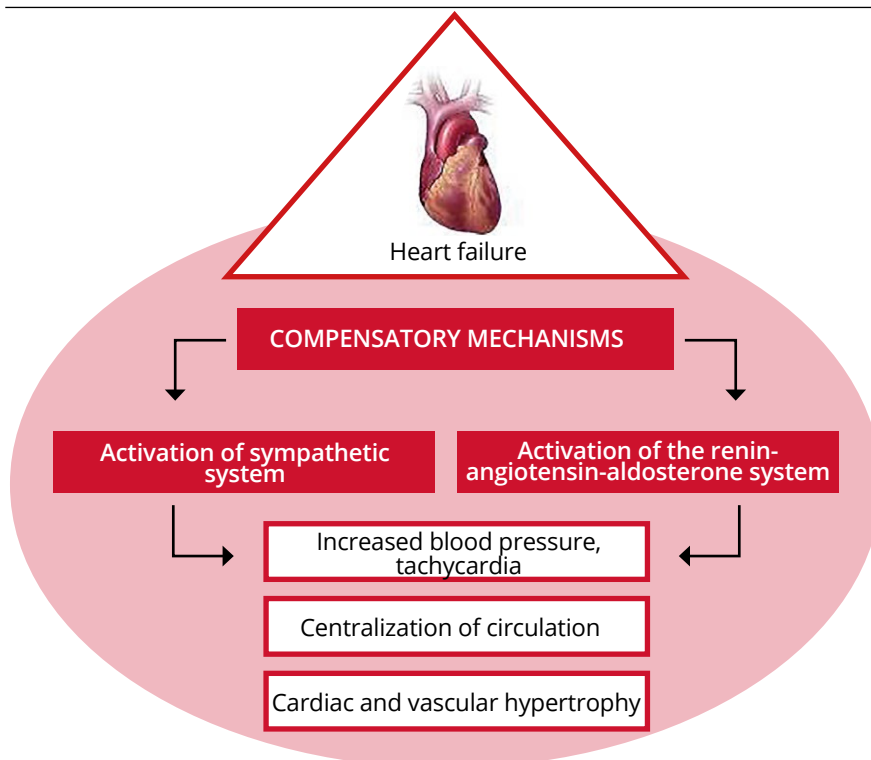


Fig. 1 Compensatory mechanisms which are activated in the body during heart failure.

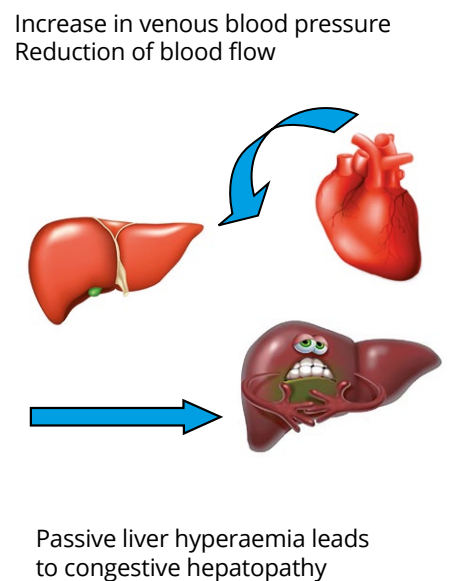


Fig. 2 Pathophysiology of congestive hepatopathy associated with chronic heart failure.



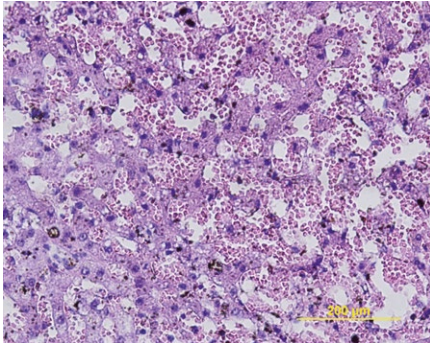


Fig. 3 Hepatic congestion in a dog euthanized due to chronic heart failure associated with degenerative mitral valve disease. H-E staining.

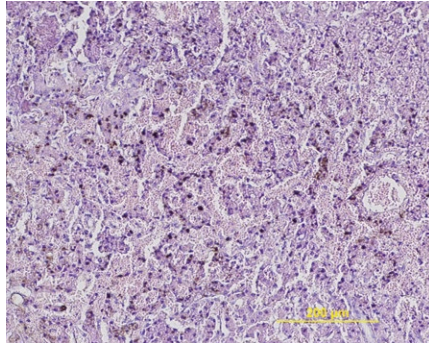


Fig. 4 Hepatic congestion in another dog euthanized due to chronic heart failure associated with degenerative mitral valve disease. As shown in Figure 3, dark brown deposits of biliary pigments (cholestasis) are visible. H-E staining.

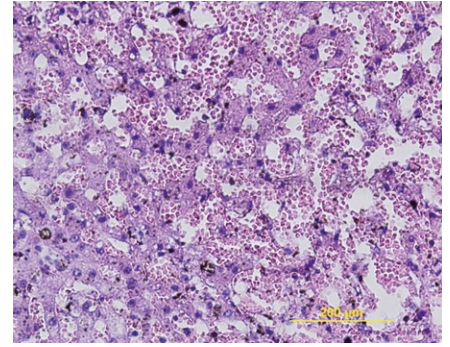


Fig. 5 Hepatic congestion and cholestasis in a dog with degenerative mitral and tricuspid valve disease. Sinusoids are dilated and filled with numerous pink erythrocytes. Iron (hemosiderin) and pigments are visible as dark clusters. H-E staining.

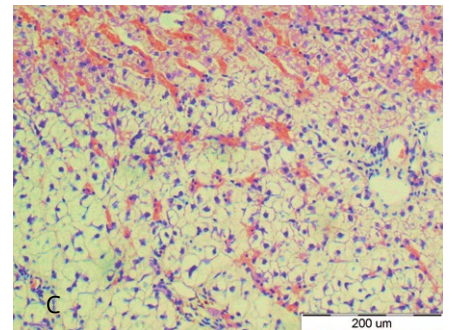
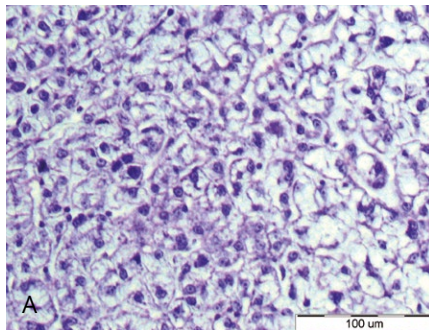
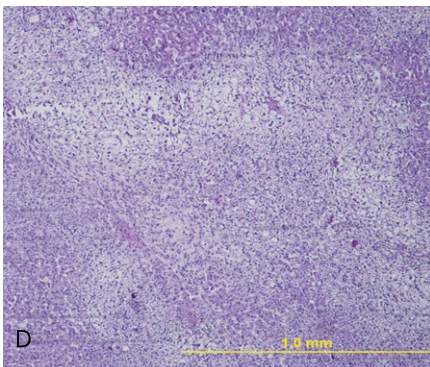
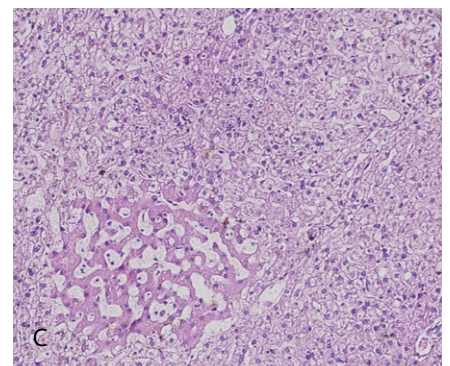
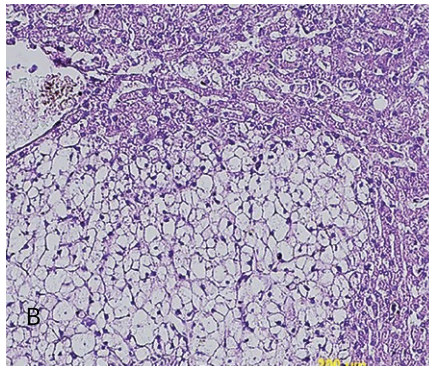
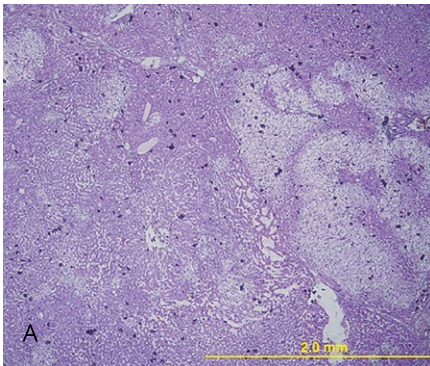


Fig. 6 Hepatic degeneration and necrosis in four dogs with advanced degenerative mitral valve disease: A) fatty degeneration (steatosis) covers large areas of the hepatic parenchyma; focal lesions, B) macrovesicular steatosis; C) degenerative lesions causing a Zahn's infarct; D) dispersed degenerative lesions in the liver. H-E staining.

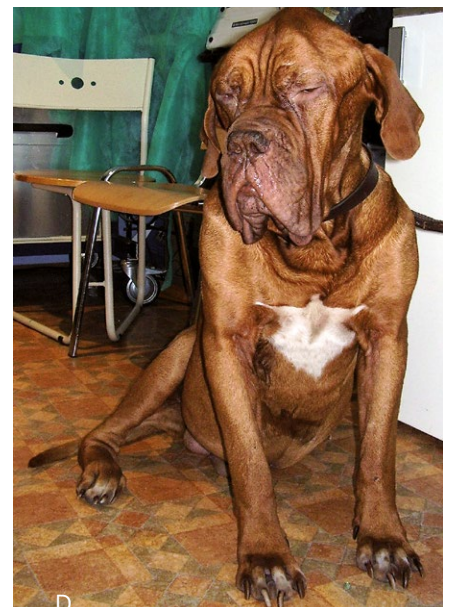
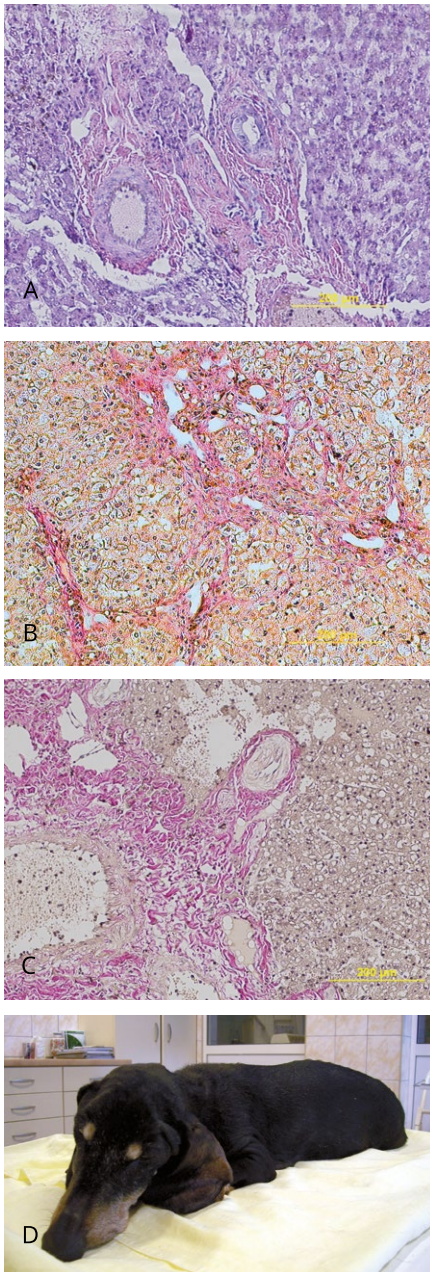
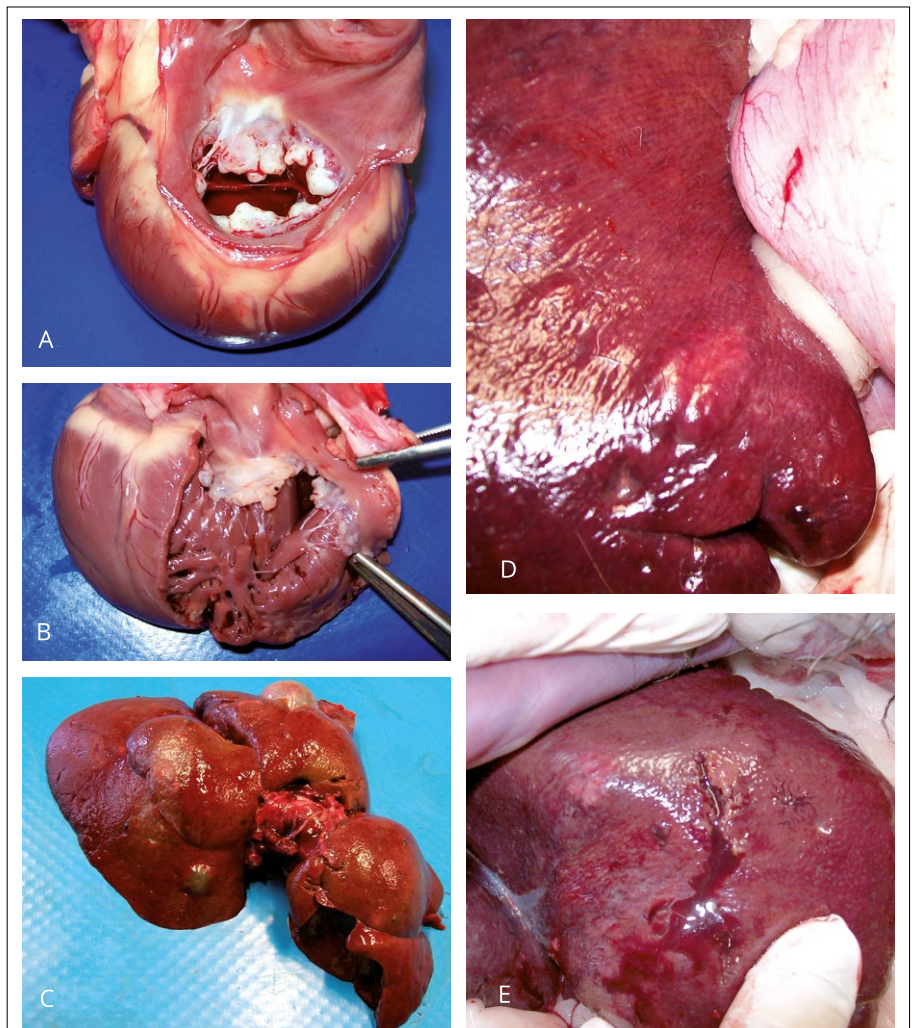


Fig. 7 Hepatic degeneration and congestion in a dog with chronic heart failure associated with degenerative mitral valve disease, A and B; and dilated cardiomyopathy, C and D. H-E staining.





**Fig. 8** A and C: degeneration of the hepatic parenchyma and severe fibrosis in the portal spaces in a dog euthanized due to terminal heart failure caused by degenerative mitral valve disease. Arterial wall hypertrophy (arrow). H-E staining. B and D: severe fibrosis in the portal spaces. Van Gieson staining. The connective tissue is pink and red, and the hepatic tissue is yellow and brown. D: fibrosis, fatty degeneration, cholestasis, congestion and vascular wall hypertrophy.



**Fig. 9** Cardiohepatic syndrome in a dog euthanized due to a degenerative disease of both atrioventricular valves (the mitral valve was affected more severely and for a longer time). A: mitral valve degeneration, viewed from the left atrium. B: degenerative lesions in the mitral valve, the anterior cusp is more severely affected. Apart from the deformations of the cusp margin, there is complete opacification of the cusp, C, and D: the liver with gross lesions. The organ is enlarged, the contour has lost sharpness (hepatic congestion and oedema), and the foci of degeneration and regeneration have contributed to uneven surface and contours. C and E: some bulged areas are changed in colour; they are ivory or dark red and brown (almost black).

The increased venous pressure leads to the widening of foramina in the sinusoids and leakage of protein-rich fluid into the space of Disse, which causes hepatocyte necrosis (Giallourakis) (Fig. 6).

The disturbances in hepatic circulation do not usually cause any clinical symptoms but when heart failure exacerbates, they can produce hepatic oedema associated with congestion and stretching of the liver capsule resulting in abdominal discomfort (which is described by people as distension or bloating).

For the first time, Boland and Willius have demonstrated that almost 50% of patients with severe heart failure suffer from congestive hepatopathy. The most found lesions were atrophy and/or necrosis of hepatocytes. Both pathologies were located mainly around the central vein. The lesions

were progressively lessening towards the periphery (Boland and Willius). The area of centrilobular necrosis was spreading concomitantly with exacerbating heart failure. A decrease in venous pressure resulted in a reduction of the lesions. Similar lesions are also reported in dogs (Sepesy) (Fig. 7).

Adrenergic stimulation and activation of the renin-angiotensin-aldosterone system help to maintain arterial blood pressure (which secures the best possible blood flow through the liver and other vital organs). In the short term, these compensatory mechanisms have a positive effect but after a long time, they aggravate the pathologies, exacerbating hepatic fibrosis and causing arterial wall hypertrophy (Fig. 8).

Over the time frames with improved cardiac functioning, the liver undergoes intensive regeneration. The incredible regen-

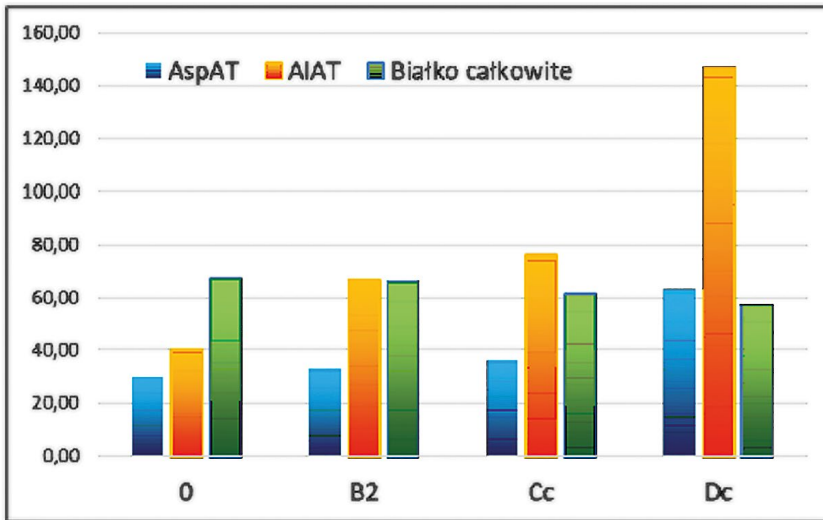


Diagram 1. The levels of alanine aminotransferase (ALAT) and aspartate aminotransferase (ASPAT) and total protein concentration in the serum of healthy dogs and dogs with heart failure associated with different stages of degenerative mitral valve disease. The classification of heart failure according to ACVIM: B2 – asymptomatic phase, Cc – moderately severe, stable (“responding” to treatment) heart failure, Dc – severe, stable heart failure.

Tab. 1 Usefulness of additional tests in diagnostics of congestive hepatopathy (Lemmer, Center)

Type of test		Importance
<b>Blood test</b>	AspaAT, AlAT, total bilirubin, total protein, albumines, INR	Low
	AP (alkaline phosphatase), GGT (gamma-glutamyl-transpeptidase)	High values suggest portal hypertension
<b>USG, CT, MRI</b>	Widening of vena cava and hepatic veins	Suggest venous hypertension
<b>Elastography</b>	Reduced elasticity	Blood stasis and/or severe fibrosis
<b>Liver biopsy</b>	Hyperaemia and secondary lesions caused by congestion	Its value depends on the accuracy of biopsy site.

Tab. 2 Medications used in the management of heart failure with a harmful effect on the liver (Samsky).

Medication	Pathology
<b>Verapamil</b>	Hepatitis
<b>Statins</b>	Acute liver injury, immune-mediated hepatitis
<b>Procainamide, diltiazem, quinidine</b>	Granulomatous hepatitis
<b>Clopidogrel</b>	Cholestasis
<b>Aspirin</b>	Acute liver injury
<b>Amiodaron</b>	Chronic hepatitis, cholestasis
<b>ACE-I</b>	Cholestasis. Lisinopril: acute liver injury, captopril: mixed hepatitis

erative capabilities of this organ are demonstrated by the results of studies conducted with people affected with terminal heart failure and referred to heart transplantation. As soon as three months after transplantation, the hepatic markers returned to normal levels (Dichtl). However, the regeneration process does not restore the primary hepatic architecture. Disorganized growth leads to the development of foci which grossly resemble neoplastic proliferation and make the hepatic surface and contours uneven (Fig. 9).

The adjacent areas with severe regressive lesions such as fatty degeneration and cholestasis give the liver a slightly yellow tint. Such yellowish and thin rims surround dark red points (congestion of the centrilobular area); a characteristic bicolour appearance of the liver is referred to as a nutmeg liver (hepar moschatum). Concomitant or consecutive series of fibrosis and regeneration (with “shrinking” of the fibrotic tissue) can make the liver size unchanged.

### Clinical diagnostics of liver injury

Blood tests are usually performed to confirm hepatocyte injury, which correlates with elevated levels of aminotransferases (ASPAT and ALAT), lactate dehydrogenase, and total bilirubin. However, these changes seem not to be related to hepatomegaly (Kubo); the reason for this can be the complexity of factors which determine the liver size. In people with severe liver failure, blood tests show the abnormalities typical of cholestasis such as increased levels of alkaline phosphatase (AP), gamma-glutamyl transpeptidase (GGT), and hypoalbuminemia (Lau). Hypoalbuminemia is a common complication of heart failure in humans. The study performed by Alen et. al. showed a decreased concentration of albumins in about 25% of patients (Allen). It was initially related to aberrant nutrition or overhydration and loss of albumins via the kidneys. The studies which have been performed over the last decades suggest inflammation as an additional contributing factor. The inflammatory reaction can be triggered by the degenerative lesions of hepatocytes, and at later stages, inflammation itself can spontaneously change the regulation of hepatic protein metabolism (Horwich). The studies conducted with 70 dogs (18 healthy dogs and 58 dogs with chronic heart failure) have demonstrated that the changes in the blood parameters are similar to the abnormalities described in people. The elevated levels of ASPAT and ALAT and a reduction in the total protein concentration have been reported. Like in humans, the degree of changes correlates with the stage of the disease; however, in dogs, changes in the blood parameters seem to be of a lesser degree (Diagram 1).

The changes in the levels of metabolic enzymes and transport proteins together with the reduction in plasma protein synthesis do not change only the basic systemic metabolism but also affect the pharmacokinetics of





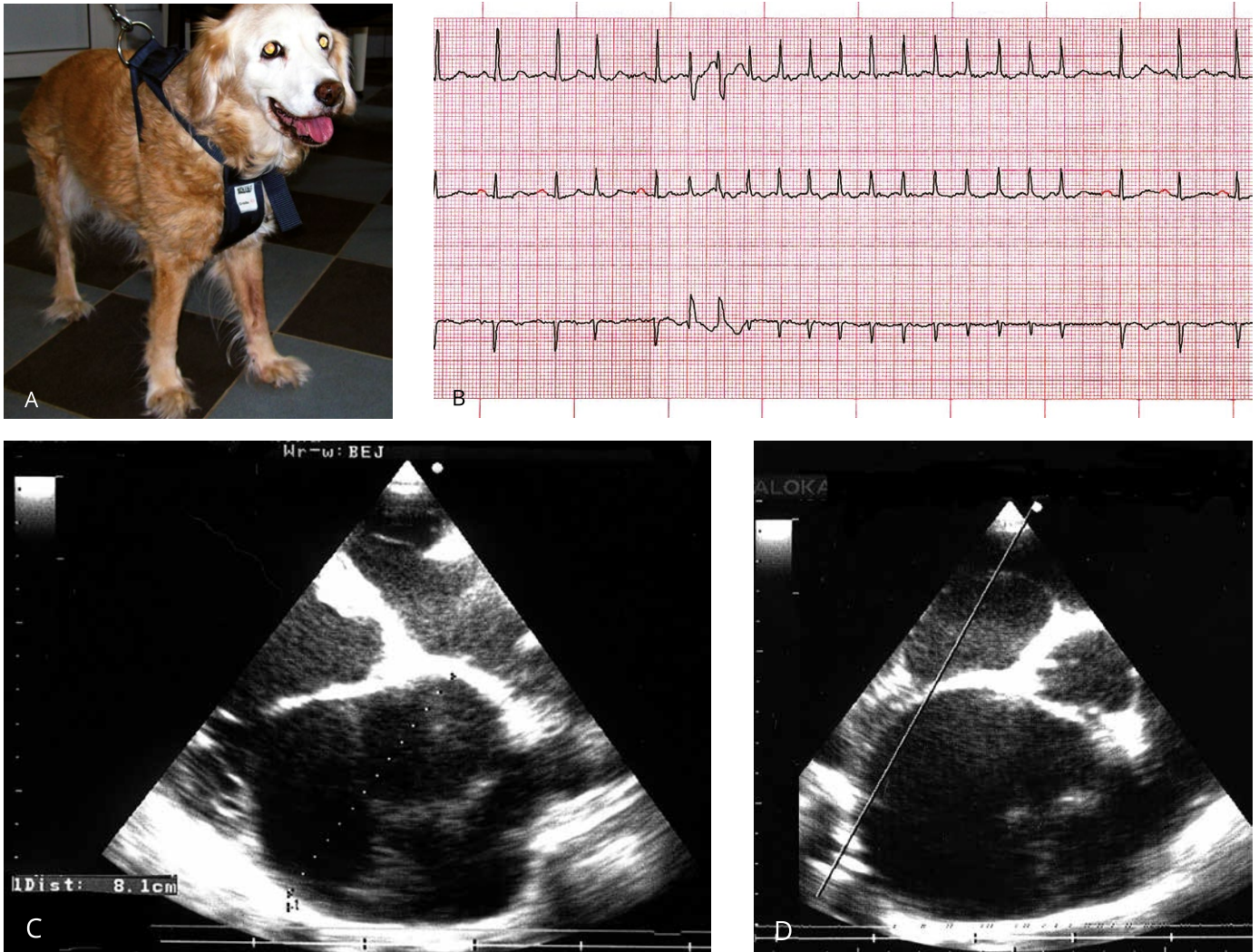


Fig. 10 A: a dog with advanced chronic heart failure. Apart from complex arrhythmia (A) (atrial fibrillation, a couple of premature ventricular complexes), mitral valve degeneration (B, C), eccentric hypertrophy of the left ventricle and the left atrial dilation there are thrombi visible in the left atrium. ECG: I, II, III, 25 mm/se, 1mV=10 mm limb leads. Echocardiography, D: parasternal four-chamber view, C: right parasternal vascular view.

administered medications.

The basic indicator of liver function is hepatic clearance. It is defined as the volume of blood from which the medication is eliminated by the liver in the time unit. Hepatic clearance depends (it is a function) on the hepatic blood flow (Verbeeck). Therefore, a reduction in the blood flow disturbs the normal transformation and elimination of medications.

The studies have confirmed that these abnormalities correlate with the severity of heart disease (Hepner). Interestingly, there are clear guidelines about using specific medications in kidney dysfunction but the modifications of doses, frequency of dosing or application in hepatic dysfunction have not been determined (Samsky). It is even more difficult as it requires anticipating all potential interactions of medications and adequately modifying the doses. At the same time, the liver function should be considered. Therefore, it is a big clinical challenge. Most cardiologists strive to meet the challenge and pay particular attention to the liver during the clinical examination. If it is necessary, they also perform additional tests and make use of their own experience. It is be-

lieved that the more disturbed the liver function is, the more intense the accumulation of medications. Accordingly, the daily dose is proportionally reduced. It is especially important for the medications with a narrow therapeutic index or the medications which exacerbate the pathologies associated with liver dysfunction, for instance, anticoagulant agents.

An additional factor which complicates the management of dogs with heart failure is that some medications for heart conditions exert a negative impact on the liver (they damage hepatocytes or disturb their functioning) (Table 2).

As already mentioned, liver failure disturbs the production of coagulation factors. Due to a high functional reserve of the liver, these disturbances do not carry clinical significance unless heart failure is at a very advanced stage. The most common findings are coagulation homeostasis disturbances; on one hand, they make the animal susceptible to the formation of thrombi in the heart chambers (usually in the left atrium), and on the other hand, they make them prone to petechiae (Fig. 10 and 11).

Iron metabolism disorders associated with

chronic heart failure are a very interesting issue which has been intensively investigated over the last few years. It has been demonstrated that the liver plays an important role. Iron is excessively accumulated in the liver, which translates into hemosiderin deposits on histopathological slides. The iron deposits slowly become biologically unavailable, and as a result, anaemia develops and significantly deteriorates the prognosis in patients with heart disease (Fig. 12).

The key role played by the liver plays in metabolism (and its impact on cardiac failure and the development of secondary disorders) indicates how important it is to protect the organ. In many cases, it is not possible to compensate for the cardiovascular failure or avoid using hepatotoxic medications. Therefore, the concept of protecting the liver and compensating for metabolic disorders with a diet has emerged over the last few years. So far, the only criterion to be met by the cardiac diets has been a limited sodium content. As the clinical practice has indicated, it is not enough, and further work on the diet composition is warranted to create the diet with the other nutrients.



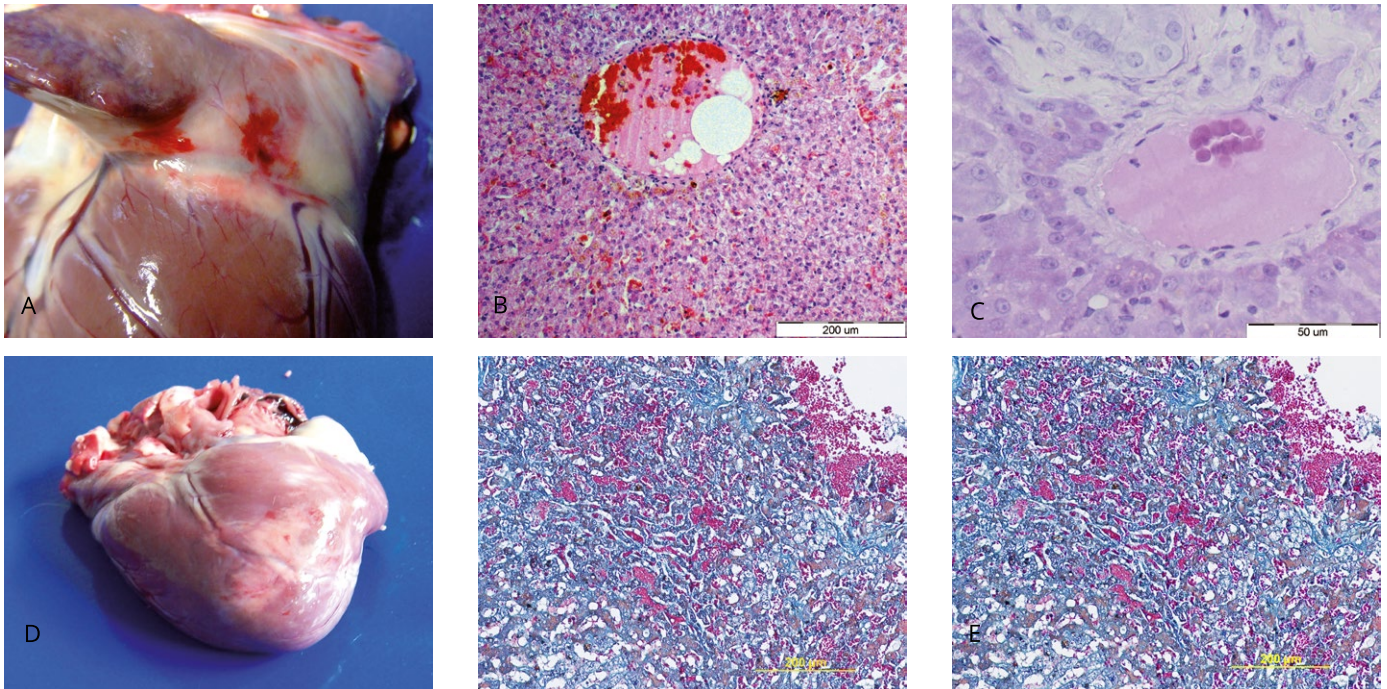


Fig. 11 A: heart at necropsy collected from a patient with terminal heart failure; petechiae under the auricle of the left atrium. Coagulation disorders were exacerbated after the administration of clopidogrel. B and C: a histopathological examination of the liver. Hyperaemia, degeneration, and necrosis are demonstrated, and there is a red and white clot in the vessel. H-E staining. D: minor pinpoint and streaky haemorrhages under the left ventricle epicardium. E and F: congestion and ecchymoses (arrow) in the liver. Mallory staining.

References:

- Allen LA, Felker GM, Pocock S, et al. Liver function abnormalities and outcome in patients with chronic heart failure: data from the Candesartan in Heart Failure: Assessment of Reduction in Mortality and Morbidity (CHARM) program. *Eur J Heart Fail* 2009;11:170-7.
- Boland EW, Willius FA. Changes in the liver produced by chronic passive congestion: with special reference to the problem of cardiac cirrhosis. *Arch Intern Med* 1938;62:723-39.
- Center SA, Stater MR, Manwarren T, Prymak K. Diagnostic efficacy of serum alkaline phosphatase and gamma-glutamyltransferase in dogs with histologically confirmed hepatobiliary disease: 270 cases (1980-1990). *J Am Vet Med. Assoc.* 1992; 15(8), 1258-1264.
- Dichtl W, Vogel W, Dunst KM, et al. Cardiac hepatopathy before and after heart transplantation. *Transpl Int* 2005;18:697-702.
- Giallourakis CC, Rosenberg PM, Friedman LS. The liver in heart failure. *Clin Liver Dis* 2002;6:947-67.
- Hepner GW, Vesell ES, Tantum KR. Reduced drug elimination in congestive heart failure. Studies using aminopyrine as a model drug. *Am J Med* 1978;65:371-6.
- Horwich TB, Kalanter-Zadeh K, MacLellan RW, Fonarow GC. Albumin levels predict survival in patients with systolic heart failure. *Am Heart J* 2008;155:883-9.
- Kubo SH, Walter BA, John DH, Clark M, Cody RJ. Liver function abnormalities in chronic heart failure. Influence of systemic hemodynamics. *Arch Intern Med* 1987;147:1227-30.
- Lau GT, Tan HC, Kritharides L. Type of liver dysfunction in heart failure and its relation to the severity of tricuspid regurgitation. *Am J Cardiol* 2002;90:1405-9.
- Lemmer A, VanWagner L, Ganger D. Congestive hepatopathy: Differentiating Congestion from fibrosis. *Clinical Liver Disease* 2017, 10(6), 139-143.
- Paślowski R, Paślowska U, Szczepankiewicz B. Kardionefrologia – nowy punkt widzenia w medycynie weterynaryjnej. *Weterynaria w Praktyce* 2020, 17(3), 66-74.
- Samsky MD, Patel ChB, DeWald TA, Smith AD, Fel-

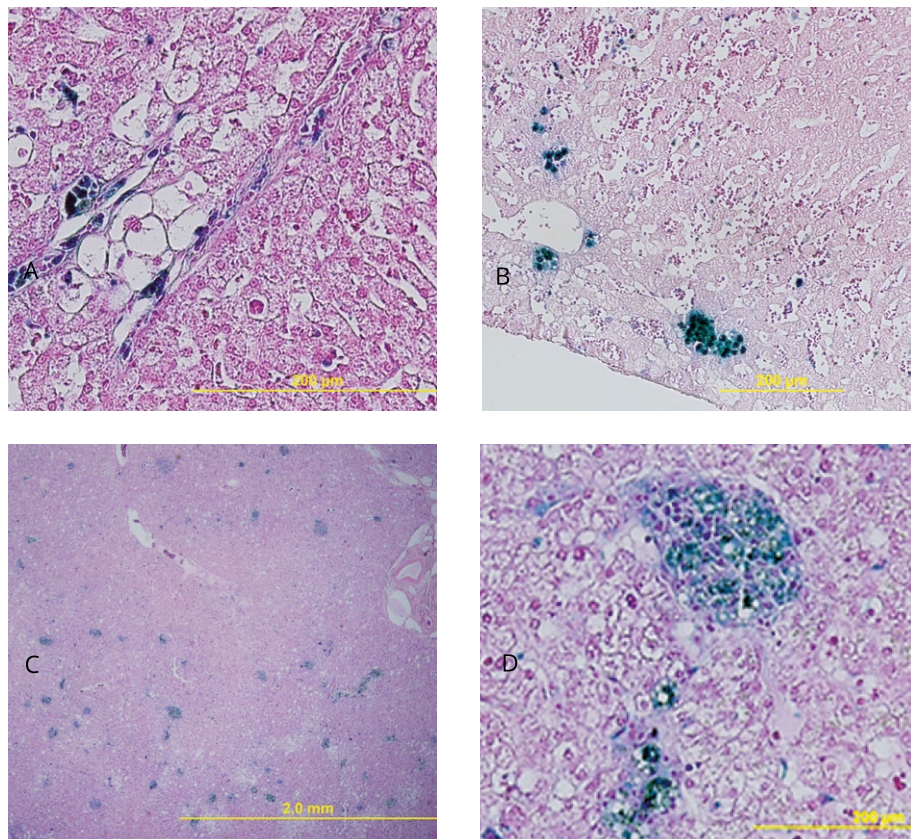


Fig. 12 Hemosiderin deposits in the liver; D: a zoomed region of C image. H-E staining.

- ker GM, Rogers JG, Hernandez AF. Cardiohepatic Interactions in Heart Failure. An Overview and Clinical Implications. *Journal of the American College of Cardiology.* 2013, 61(24), 2397-405.
- Sepesy LM, Center SA, Randolph JF, Warner KL, Erb HN: Vacuolar hepatopathy in dogs: 336 cases (1993-2005).
- Szczepankiewicz B, Paślowska U. Szorstka przyjaźń, czyli syndrom kardionefrologiczny. *Weterynaria w Praktyce*, 2018, vol. - dodatek kardiologiczny, 13-18.

- Verbeeck RK. Pharmacokinetics and dosage adjustment in patients with hepatic dysfunction. *Eur J Clin Pharmacol* 2008; 64:1147-61.





# To Support or Not To Support – supplements in dogs with advanced heart failure

Magdalena Garncarz DVM PhD, Marta Parzeniecka-Jaworska DVM PhD

Department of Pathology and Veterinary Diagnostics, Faculty of Veterinary Medicine, Warsaw University of Life Sciences – SGGW, Poland



## INTRODUCTION

For a long time, supportive treatments for patients with heart diseases have been in use in different forms. Some commercial products contain L-carnitine, a substance necessary for the normal metabolism of fatty acids and energy production; taurine which plays a crucial role in the physiological functioning of the heart; coenzyme Q10 (ubiquinone) which is important for cardiac energy metabolism; and vitamin E with potent antioxidative properties like coenzyme Q10 or taurine. In dogs with different heart failure stages, it is difficult to compare the efficacy of the substances without resorting to standard management such as diuretics, inodilators, angiotensin-converting enzyme inhibitors (ACE), and antiarrhythmic agents. Therefore, the authors have tried to evaluate how dogs affected with different stages of heart disease feel.

## MATERIALS AND METHODS

The study was carried out with 36 dogs of different breeds, aged from 36 to 222 months, including 10 females and 26 males. The majority of dogs were diagnosed with chronic mitral valve disease (CMVD, 25 dogs) while the others had the diagnosis of dilated cardiomyopathy (DCM, 11 dogs). A transthoracic echocardiographic examination was performed in all dogs. Moreover, a chest X-ray was used to detect left-sided congestive heart failure. The stage of heart failure was determined with widely approved standards and according to the classification of the International Small Animal Cardiac Health Council (ISACHC). Conforming to the classification, dogs with CMVD or DCM were categorised into Class 1 (asymptomatic, n = 9), Class 2 (mild to moderate heart failure, n = 16) or Class 3 (advanced heart failure, n = 11). On the consultation day, the dogs classified as ISACHC Class 2 and 3 received a supplement dedicated to dogs with heart failure to complement the standard management. The supplement's composition includes L-carnitine tartrate 500 mg, taurine 200 mg, Q10 coenzyme 10 mg, and vitamin E 60 IU per tablet (CardioVet, Vet Expert). The product was administered according to the manufacturer's recommendations. After a month, during the follow-up visit, the owners were asked to describe their observations on the well-being and comfort of the dog, focusing on exercise tolerance during walks, respiratory symptoms (tachypnoea), and cough.

## RESULTS

Among nine dogs classified as ISACHC Class 1, the owners of three patients reported improved exercise tolerance, describing their dogs as being livelier with the supplementation compared to the period before the management with the supplement (33.3% of ISACHC Class 1 dogs, 8.3% of all investigated dogs). According to the owners, exercise tolerance improved in 12 of 16 ISACHC Class 2 dogs; the owners described their dogs as livelier (75% of ISACHC Class 2 dogs, 33.3% of all investigated dogs). The group included eight dogs with CMVD and four dogs with DCM. In the case of 11 dogs with advanced heart failure categorised into ISACHC Class 3, exercise tolerance improved in nine dogs (81.8% of ISACHC Class 3 dogs, 25% of all investigated dogs), and it translated into two out of three dogs with DCM and seven out of eight dogs with CMVD. Coughing frequency decreased in two dogs, including one with CMVD and one with DCM (18.2% of ISACHC Class 3 dogs, 5.6% of all investigated dogs).

## SUMMARY

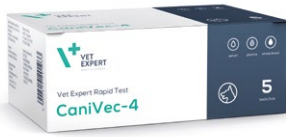The study demonstrated a favourable effect of the investigated product on the animals with advanced heart failure. The study product contributed to the improvement of exercise tolerance in most dogs, although the evaluation of exercise tolerance was based on the subjective assessments made by the owners. They did not observe any adverse effects of the product. The tablets were well tolerated, with no adverse events. The size of the tablets happened to be an occasional issue. In small breeds, it is necessary to crush the tablet and administer it mixed with food or water. The discussed study gives evidence of good tolerance and efficacy of CardioVet, a combination product, in dogs with advanced heart failure.

### References:

Garncarz M., Parzeniecka-Jaworska M. (2015) Wspomagać czy nie wspomagać – suplementy u psów z ciężką chorobą serca. *Magazyn Weterynaryjny*, 9, 637-643



DIFFERENTIAL DIAGNOSIS OF VECTOR-BORNE DISEASES



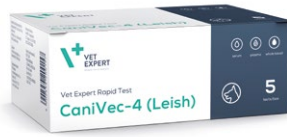**CaniVec-4**

Test detects antigen of *Dirofilaria immitis* and antibodies against *Ehrlichia canis*, *Anaplasma* spp., *Borrelia burgdorferi*.

**Sensitivity:** Heartworm 99.9%, *E.canis* 98.2%, Lyme 93.0%, *Anaplasma* 96.1%

**Specificity:** Heartworm 99.9%, *E.canis* 99.9%, Lyme 98.0%, *Anaplasma* 99.3%

**Box size:** 5



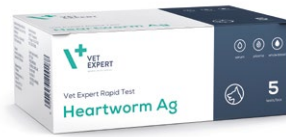**CaniVec-4 (Leish)**

Test detects antigen of *Dirofilaria immitis* and antibodies against *Ehrlichia canis*, *Anaplasma* spp., *Leishmania infantum*

**Sensitivity:** Heartworm 99.9%, *E.canis* 98.2%, *Leishmania infantum* 97.2%, *Anaplasma* 96.1%

**Specificity:** Heartworm 99.9%, *E.canis* 99.9%, *Leishmania infantum* 99.8%, *Anaplasma* 99.3%

**Box size:** 5/20



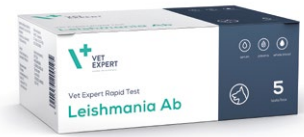**Heartworm Ag**

Test detects antigen of *Dirofilaria immitis*.

**Sensitivity:** 99.9%

**Specificity:** 99.9%

**Box size:** 5



**Leishmania Ab**

Test detects antibodies against *Leishmania infantum*.

**Sensitivity:** 97.2%

**Specificity:** 99.8%

**Box size:** 5/10/20

**Proper diagnosis of the vector-borne disease is crucial for effectively selection of the most appropriate treatment option and to convey realistic expectations of the therapy outcome.**

**When to perform the Vet Expert's vectors rapid tests in dogs?**

- ✓ In any suspected case of vector-borne disease
- ✓ As a part of differential diagnosis of thrombocytopenia and anemia
- ✓ In dogs showing cardiological and/or respiratory signs
- ✓ At least once a year as a screening test in every dog

DIFFERENTIAL DIAGNOSIS OF DIARRHEA IN DOGS AND CATS



**CPV/CCV/Giardia Ag**

Test detects antigens of canine parvovirus, canine coronavirus and *Giardia intestinalis* in dogs.

**Sensitivity:** CPV 99.9%, CCV 93.1%, *Giardia* 99.9%

**Specificity:** CPV 99.9%, CCV 97.5%, *Giardia* 99.9%

**Box size:** 5/20



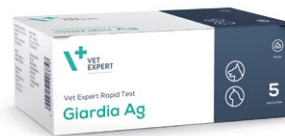**FPV/FCoV/Giardia Ag**

Test detects antigens of feline panleucopenia virus, feline coronavirus and *Giardia intestinalis* in cats.

**Sensitivity:** FPV 99%, FCoV 92.8%, *Giardia* 99.9%

**Specificity:** dia 99.9%  
Specificity: FPV 97%, FCoV 98.1%, *Giardia* 99.9%

**Box size:** 5/10



**Giardia Ag**

Test detects antigen of *Giardia intestinalis* in dogs and cats.

**Sensitivity:** 99.9%

**Specificity:** 99.9%

**Box size:** 5/10/20



**Cryptosporidium Ag**

Test detects antigen of *Cryptosporidium* spp. in dogs and cats.

**Sensitivity:** 94.4%

**Specificity:** 97.6%

**Box size:** 5

**Proper differentiation of the causative agent of diarrhea allows more complete diagnosis, introduction of targeted therapy and correct prognosis estimation.**

**When to perform the Vet Expert's diarrheas rapid tests in dogs or cats?**

- ✓ In any case of diarrhea, especially in young animals
- ✓ In animals showing other gastrointestinal symptoms such as nausea, flatulence or vomiting
- ✓ In case of insufficient response to the treatment
- ✓ In adopted or kennel animals





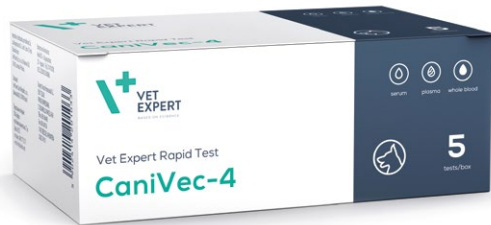

# NEW DESIGN

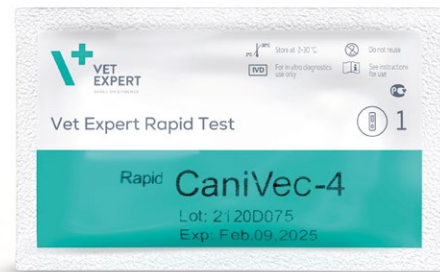## OF VET EXPERT RAPID TESTS

### CONSISTENTLY OF THE HIGHEST QUALITY


### NEW PACKAGING DESIGN



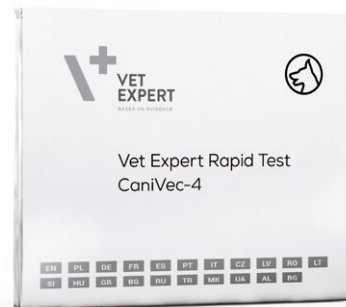### NEW POUCHES



### NEW CASSETTES



### NEW INSERTS



## CHANGED TEST NAMES

Vet Expert Rapid Test CaniV-4

Vet Expert Rapid Test CaniV-4 (Leish)

Vet Expert Rapid Test CIRD-3 Ag

Vet Expert Rapid Test Felicheck-3

Vet Expert Rapid Test BoviD-4 Ag



Vet Expert Rapid Test CaniVec-4

Vet Expert Rapid Test CaniVec-4 (Leish)

Vet Expert Rapid Test CaniRespi-3

Vet Expert Rapid Test FIV/FeLV/FHW

Vet Expert Rapid Test Calfdiar-4

**NOTE** – Other rapid tests do not change their names.

## HEART SUPPORT



### CardioVet



#### Supports heart function

A supplement recommended for dogs suffering from heart diseases. It contains high concentrations of ingredients that boost the function of the heart muscle. CardioVet can be administered alongside cardiac medication or, in the case of mild disorders, as a natural supplement to support heart function.

**Composition:**

L-carnitine 540 mg, taurine 200 mg, vitamin E 120 mg, selenium yeast 10 mg.

**Packaging:**

90 tablets

**Dosage:**

<15 kg BM – 1 tablet twice daily  
>15 kg BM – 2 tablets twice daily

## SUPPORT OF HEMATOPOIESIS IN CASE OF IRON DEFICIENCY



### HemoVet



#### Easily assimilable heme iron

Uniquely designed for anemic dogs, the product contains the key substances necessary for haematopoiesis. It can be administered to support the treatment for Babesia canis, regenerative anemia, autoimmune hemolytic anemia, as well as to support recovery after splenectomy. It supports bone marrow function, supplies easily assimilable heme iron, boosts the formation of red blood cells, and reduces recovery time.

**Composition:**

Heme iron 30 mg, copper 20 mg, vitamin B6 0.60 mg, vitamin B12 0.01 mg, folic acid 0.03 mg, vitamin C 30 mg.

**Packaging:**

60 tablets

**Dosage:**

1 tablet per 10 kg BW daily

## RENAL SUPPORT



### RenalVet



#### Irreplaceable support in kidney failure

Recommended for cats and dogs suffering from chronic kidney disease. Administered at meal time, the phosphorus-chelating agent effectively reduces the absorption of phosphorus from the gastrointestinal tract, lowers phosphorus levels in the serum, decreases the concentration of parathormone, and reduces the excretion of phosphorus in urine. The supplement also prevents potential vitamin D deficiencies.

**Composition:**

Calcium carbonate 200 mg, chitosan 100 mg, vitamin D 0.08 mg

**Packaging:**

60 Twist Off capsules


**Dosage:**

Cats and dogs <10 kg bw  
– 1 capsule daily  
Dogs >10 kg bw – 1 capsule per 10 kg bw daily



# COMPREHENSIVE PROTECTION AND SUPPORT LIVER FUNCTION

PREPARATIONS INTENDED FOR DOGS AND CATS  
TO HELP SUPPORT THE PROPER LIVER FUNCTION



Product	Hepatiale Forte Small Breed	Hepatiale Forte	Hepatiale Forte Large Breed	Hepatiale Forte Liquid	Hepatiale Forte Advanced
Form					
Instruction for proper use	1 capsule/5 kg bw	1 tablet/15 kg bw	1 tablet/25 kg bw	5 ml/10 kg bw	1 tablet/10 kg bw
Composition	phospholipids, glutamine, arginine	phospholipids, glutamine, arginine	phospholipids, glutamine, arginine	milk thistle (source of sylimarin), betaine, L-carnitine, choline chloride, artichoke	Betaine, arginine, glutamine, milk thistle (source of sylimarin), phospholipids, zinc
Species and size of dogs	Cats and small breed dogs	Medium breed dogs	Large breed dogs	Only dogs	Cats and dogs

## SUGGESTED COMBINATION OF DIAGNOSTIC TESTS, SUPPLEMENTS AND DIET

DISEASE/ORGAN	QUICK DIAGNOSTICS			SUGGESTED TREATMENT SUPPORT							
	Vet Expert Vcheck			SUPPLEMENT				DIET			
	Canine NT-proBNP	Feline NT-proBNP	D-dimer	CardioVet	RenalVet	HemoVet	Hepatiale	HEPATIC	RENAL	RECOVERY	
HEART				x							
HEART + LIVER				x			x	x			
HEART + KIDNEY				x	x					x	
HEART + LIVER+ KIDNEY				x	x		x			x	
HEART + Fe DEFICIENCY				x		x					
CARDIAC KACHEXIA	x							x			



NEW



# STIMUDERM ULTRA

INNOVATIVE SUPPORT  
OF ALOPECIA TREATMENT  
IN DOGS



Unique formula based on scientifically proven\* **ACTIVE NTM™** molecule stimulating hair regrowth.



Completely innovative range of products based on unique solutions.



The only integral dermoprogram on the market supporting alopecia treatment in dogs.



Specialized, premium veterinary dermocosmetics.

\* Confirmed in clinical trial: Popik M. „1-metylonikotynamid jako modulator fizjologicznego i dystroficznego cyklu włosowego myszy C57B1/6.” („1-methylnicotinamide as a modulator of physiologic and dystrophic hair cycle of mice C57BL/6.”) PhD thesis. The Faculty of Biochemistry, Biophysics and Biotechnology UJ. 2008.